

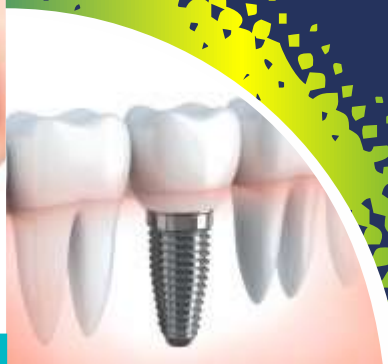

[www.idakochi.org](http://www.idakochi.org)

# JIDAK

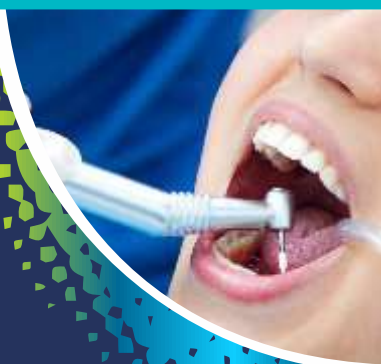Jul.- Dec. 2024, Volume 6, Issue 2

JOURNAL OF INDIAN DENTAL ASSOCIATION - KOCHI



INDIAN DENTAL ASSOCIATION

KOCHI BRANCH







[www.idakochi.org](http://www.idakochi.org)

# JIDAK

Jul. - Dec. 2024, Volume 6, Issue 2

## JOURNAL OF INDIAN DENTAL ASSOCIATION - KOCHI

Journal of Indian Association of Kochi Branch (JIDAK) is the official scientific publication of Indian Dental Association, Kochi Branch. It is a peer-reviewed journal published quarterly in e-format as well as print format.

The journal invites manuscripts from dental and other allied health sciences. It publishes manuscripts under categories of Original Research, Review and Case Reports.

For submission of manuscripts,  
log on to [www.jidakochi.org](http://www.jidakochi.org).  
For communications,  
mail to [jidakochi@gmail.com](mailto:jidakochi@gmail.com).

### Editorial Board

Dr Tatu Joy (Oral Medicine & Radiology)  
Dr Nithin Thomas (Oral Medicine & Radiology)  
Dr Eldo Koshy (Prosthodontics)  
Dr Cherian KP (Prosthodontics)  
Dr Korath Abraham (Pedodontics)  
Dr Bhat Sangeetha Govinda (Pedodontics)  
Dr George Jacob (Conservative Dentistry & Endodontics)  
Dr Prashanth Dhanpal (Conservative Dentistry & Endodontics)  
Dr Vivek Narayan (Periodontics)  
Dr Rajesh Vylopillil (Periodontics)  
Dr KS Skaria (Oral Pathology)  
Dr Vinod Kumar R B (Oral Pathology)  
Dr Jaibin George (Implantology)  
Dr Prasanth Pillai (Implantology)  
Dr Prasanth Pratap (Orthodontics)  
Dr Gopikrishnan S (Orthodontics)  
Dr Pooja Latti (Public Health Dentistry)  
Dr Ram Mohan (Oral & Maxillofacial Surgery)  
Dr Binu Augustine (Oral & Maxillofacial Surgery)

### EDITORIAL BOARD

#### Chief Editor

Dr Joy Kurian

#### Editor-in-charge

Dr. Bindu Rachel Thomas

#### Advisory Board

Dr V I Paul  
Dr Siby T Chennankara  
Dr Meera Gopalakrishnan  
Dr Subramaniam R  
Dr Vidhya Parameswaran  
Dr Raju Kurian Ninan

## FOREWORD

The field of dentistry is constantly evolving, driven by advancements in technology, research, and clinical practice. In this dynamic environment, it is crucial for dental professionals to stay abreast of the latest developments and innovations. The Journal of Indian Dental Association Kochi serves as a vital platform for fostering this ongoing discourse and exchange of ideas.

As we embark on yet another journey of academic excellence and knowledge dissemination, I extend my heartfelt gratitude to all the contributors, editors, and reviewers who have made this endeavour possible.

Through its comprehensive coverage of various aspects of dentistry, this journal aims to enrich the knowledge and skills of dental practitioners. Our dedicated team of editors and reviewers ensures that each article published in the journal upholds the highest standards of quality and relevance.

I am particularly proud of the contributions from our esteemed members and colleagues, whose expertise and insights continue to drive excellence in dental care. Their commitment to advancing the field of dentistry is truly commendable.

I extend my best wishes to the editorial team, authors, and readers of the JIDAK. May this journal serve as a beacon of knowledge and innovation in the field of dentistry for years to come.

Warm regards,



Dr Vinod Thamby  
President  
IDA, Kochi

## Secretary's Message

Dear IDA Kochiute,

It is quite surprising to observe that despite being so well connected these days, genuine communication often takes a back seat in our relationships. We are constantly in touch with each other - at a pace that is sometimes baffling.

Somehow, I am compelled to ask. Have we really touched each other's lives meaningfully? The truth is certainly hard to run away from.

JIDAK is our voice on a stage called the World. To make some noise is your choice. This first edition is resplendent with pages of intellect, intent and information. While it connects us as a family, it serves to showcase us in many special ways.

It is a proud reflection of the depth that we carry in our fraternal bonding and the immense responsibility we choose to uphold as professionals.

I am reassured that you will encourage it as a platform to blend your views, mend your thoughts and send your words of worth, in the future.

My warmest wishes are reserved for the Editorial Board in bringing life to these pages, even as I urge you to take a few moments to relish the fruit of their earnest efforts.

Yours sincerely,



Dr Brijitha Manoj  
Hon Secretary  
IDA Kochi

## Chief Editor's Message

*Dear Friends*

*Greetings from the editorial desk...*

It's with immense pleasure that I bring forth the first edition of the term. I really appreciate and thank the contributors and the office bearers and the media team who work tirelessly to make it happen. We have carefully selected the articles to enlighten the clinicians and academicians. May this enlighten and enrich the audience.



---

Dr Joy Kurian  
Chief Editor- JIDAK  
IDA Kochi

---

# CONTENTS

## **OZONE:**

### **A PANACEA TO PEDIATRIC DENTISTRY**

Krishnapriya Vidyadharan, Archana G Vijayan

Soumya Rajan, Amla Prasad S, Anjali S

8-16

### **MANAGEMENT OF PREGNANT PATIENT**

#### **IN ORTHODONTIC PRACTICE**

Nisha C Joseph, Dhanya M, Binnoy Kurian

17-23

### **AI IN ENDODONTICS; WHERE ARE WE NOW?**

Akhila Surendran, Vishnuraj P R

24-30

### **ORTHODONTIC TREATMENT IN DIABETIC PATIENTS:**

#### **CHALLENGES AND CONSIDERATION**

Vidya S L, Shikha B, Binnoy Kurian

31-35

### **ORTHODONTIC CORRECTION OF A TRANSPOSED**

#### **MAXILLARY LATERAL INCISOR AND CANINE**

Joseph Varghese

36-42

### **CUSHING'S SYNDROME:A SUMMATION**

Bastin Bright Cherian, Sharlene Sara Babu, Sunil S

43-46

# OZONE: A PANACEA TO PEDIATRIC DENTISTRY



## ABSTRACT

In the medical field, ozone has long been employed with success. It can be practically used in all areas of dentistry. It is a bio oxidative therapy that produces the desired therapeutic results when administering oxygen or ozone via gas, water, or oil. The antibacterial, disinfecting, and biocompatible qualities of ozone are being used therapeutically in pediatric and general dentistry. Together with these properties, it has antihypnotic, analgesic, immunostimulant, anti-inflammatory, detoxicating, bioenergetic and biosynthetic effects. In pediatric dentistry, it is used in treatment of initial fissure caries, for eradication of bacterial count in pulpectomy, management of avulsion, reducing the post-extraction healing time and decontamination of toothbrush. Since, ozone therapy is fast and painless, it increases operator efficiency in addition to patient tolerance with minimal adverse effects, thus making it an ideal treatment choice for pediatric patients.

## Authors:

Krishnapriya Vidyadharan<sup>1</sup>  
Archana G Vijayan<sup>2</sup>  
Soumya Rajan<sup>3</sup>  
Amla Prasad S<sup>4</sup>  
Anjali S<sup>5</sup>

<sup>1,2</sup>PG Student

<sup>3</sup>Professor & Head

<sup>4,5</sup>Assistant Professor

Sri Sankara Dental College  
Varkala.

J Ind Dent Assoc Kochi 2024;6(2):8-16.



## INTRODUCTION

Ozone (also known as triatomic oxygen and trioxygen) is a naturally occurring compound consisting of three oxygen atoms. In dentistry, Dr. E.A. Fisch (1899-1966) was the first dentist to use ozonated water in his practice and introduced it to the German surgeon Dr. Erwin Payr (1871-1946) who used it from that time forward in surgery and reported his results at the 59th Congress of the German Surgical Society in Berlin (1935).<sup>1</sup>

Ozone therapy can be defined as a versatile bio-oxidative therapy in which oxygen/ozone is administered via gas or dissolved in water or oil base to obtain therapeutic benefits. Interest of Ozone use in medicine and dentistry is due to its anti-microbial, disinfectant, biocompatibility and healing properties.<sup>2</sup>

The Greek word "ozein," which denotes an odorant or fragrant substance, is where the name "ozone" comes from. It exists organically as a strong-smelling gas in the lower stratosphere, with its primary purpose being to absorb hazardous UV radiation that is part of the sun's light spectrum and therefore safeguard life on Earth.<sup>4</sup> It was first used in 1840 by German chemist Christian Friedrich Schonbein "The father of ozone therapy."<sup>3</sup>

### Fundamental forms of application to oral tissues:

#### (1) Ozonated water

Dr. Kramer points out that ozonated water can be used in a number of different ways:<sup>7</sup>

1. As a mouth rinse especially in the cases of gingivitis, periodontitis, thrush or stomatitis;
2. As a spray to cleanse the affected area, and to disinfect oral mucosa, cavities and in dental surgery;
3. As a ozone /water jet to clean cavities to teeth being capped, receiving root canal therapy, and in treating painful gingivitis and stomatitis.

#### (2) ozonated olive oil

Ozonated oils are naturally occurring derivatives of plant extracts.<sup>5</sup>

They undergo a chemical reaction to form a thick, viscous oil, or in some cases, a petroleum jelly-like product contain ozonides.<sup>3</sup>

Mycobacteria, Staphylococci, Streptococci,

Enterococci, Pseudomonas, and Escherichia coli are all susceptible to ozonized oil (Oleozone and Bioperoxoil).<sup>5</sup>

### (3) Oxygen/ ozone gas

Ozone generating equipment converts oxygen to ozone.<sup>4</sup> The different systems for generating ozone gas are:<sup>5</sup>

- ✓ Ultraviolet system: It produces low concentration of ozone.
- ✓ Corona discharge system: It produces high concentration of ozone. It's the most common system used in the medical / dental field. It's easy to handle and it has a controlled ozone production rate.<sup>8</sup>
- ✓ Cold plasma system : It is used in air and water purification.

These forms of application are used singly or in combination to treat dental disease.

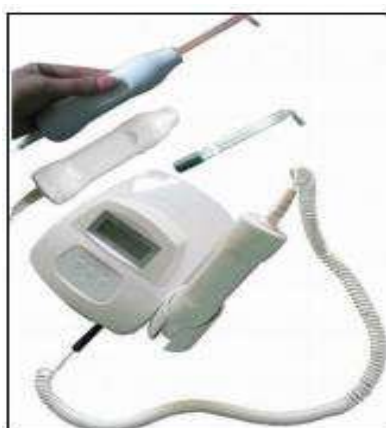### Properties of ozone:<sup>3</sup>

Ozone is colorless or slightly bluish gas (when liquefied) slightly soluble in water and much soluble in inert non polar solvents like carbon tetra fluoride and fluorocarbons. At 161K (-112°C; -170°C), it condenses to form a dark blue, liquid. It is dangerous to allow this liquid to warm to its boiling point, because both concentrated ozone and liquid ozone can detonate. Most people can detect about 0.01umol/mol of ozone in air where it has a very specific sharp odor somewhat resembling chlorine bleach. At room temperature ozone is a blue gas with a characteristic smell that can be noticed in air at a concentration of 2ppm. Ozone is thermodynamically highly unstable compound which on decomposition produces molecular oxygen, atomic oxygen which is highly reactive. Oxidizes all non noble metal immediately and attacks numerous organic compounds as a radical. This makes ozone apart from fluorine, one of the strongest oxidants. When dissolved in water, ozone is relatively unstable and decomposition rate depends on quality of water and systemic conditions.<sup>7</sup>

The first Ozone generator was created by Werner von Siemens in Germany in 1857, and C. Lender reported using it to filter blood in 1870. Werner von Siemens also invented the first Ozone generator.<sup>5</sup>

The ozone generator that is sold commercially is the HealOzone which was created by

Antimicrobial (bactericidal, viricidal, and fungicidal)	<ul style="list-style-type: none"> <li>• Damage to cytoplasmic membrane</li> <li>• Oxidation of intracellular contents</li> <li>• Specific to microbial cell</li> <li>• Effective in antibiotic resistive strain</li> </ul>
Immuno-stimulating	<ul style="list-style-type: none"> <li>• Activates cellular and humoral immune system</li> <li>• Proliferation of immune-complement cells</li> <li>• Synthesis of immunoglobulin's</li> <li>• Enhance phagocytosis activity</li> <li>• Activation of biological antioxidants</li> </ul>
Analgesic	<ul style="list-style-type: none"> <li>• Anti-hypoxic and detoxicating</li> <li>• Activation of aerobic process (Krebs cycle, glycolysis, oxidation of fatty acids)</li> </ul>
Bio-energetic and biosynthetic	<ul style="list-style-type: none"> <li>• Activates protein synthesis</li> <li>• Enhanced cell metabolism (Ribosome, mitochondria)</li> </ul>
Biologically active substances	<ul style="list-style-type: none"> <li>• Synthesis of interleukins, leukotrienes and prostaglandins</li> <li>• Synthesis of immunoglobulin's</li> </ul>



**Fig 2: Ozone generator**

CurOzone USA Inc. (Canada) for dental application and is presently sold by KaVo Dental (Biberach, Germany).<sup>5</sup>

### The HealOzone device comprises

1. An air filter.
2. A vacuum pump.
3. An ozone generator.
4. A hand piece fitted with a sealing silicone cup and a flexible hose.

Ozone is delivered through a hand piece, which is equipped with a silicon cup. Differently shaped silicone cups are available that correspond to various teeth and their surfaces. The cup is applied directly to the tooth so that it forms a tight seal at the application site.<sup>4</sup>

The procedure usually takes between 20 and 120 seconds per tooth. The ozone in the silicone cup is collected again and reconverted to oxy-

gen by the apparatus. Immediately after ozone application the tooth surface is treated with a remineralizing solution containing fluoride, calcium, zinc, phosphate and xylitol dispensed from a 2-ml ampule.

Patients are also supplied with a patient kit, which consists of toothpaste, oral rinse and oral spray, all containing fluoride, calcium, zinc, phosphate and xylitol, and aims to enhance the remineralisation process. The treatment of non-cavitated lesions is usually repeated at 3 and 6 months.<sup>7</sup>

### Composition of medical grade ozone

Medical grade ozone is a mixture of pure oxygen and pure ozone in the ratio of 0.05% to 5% of O<sub>3</sub> and 95% to 999.95% of O<sub>2</sub>. Due to the instability of ozone molecule it must be prepared immediately before use and cannot be stored over long periods of time.<sup>8</sup>

### Clinical Applications in Pediatric Dentistry

#### •Reduction in dental Anxiety in children

Most of the child patients have fear and anxiety towards dental treatment. Dahnhardt et al. In youngsters with dental anxiety, open carious lesions were treated with ozone. Anxiety was almost completely reduced (93%).<sup>6</sup> Also, 80% of the parents said they would be willing to pay more for this therapy compared with traditional drilling and filling.<sup>23</sup>

It Effectively increase patient compliance and tolerance for the therapy as well as the operator's efficiency.

### • Reduction of oral pathogens

An exposure of about 60s exhibited 99.9% killing efficiency against cariogenic bacteria such as *Actinomyces naeslundii*, *Streptococcus mutans* and *Lactobacillus casei*. However, exposure for such a long period showed degradation of salivary proteins and hence 10 s–30 s of exposure was proven to be effective in killing a significant number of bacteria. Estrela et al. demonstrated the effectiveness of ozone addition to an ultrasonic cleaning system against *Staphylococcus aureus* in infections of the oral cavity.<sup>6</sup>

Some investigators reported a reduced number of bacteria and fungi after in vivo treatment using ozonized water. In contrast, others reported no significant success of ozone treatment in reducing the microbiota. Kshitish et al. evaluated the effectiveness of ozone and chlorhexidine against certain bacteria, viruses and fungi. They recorded a 25% reduction in *A. actinomycetemcomitans* and no antimicrobial effects in relation to *P. gingivalis* or *Tannerella* for sythensis after application of ozone or chlorhexidine. The antifungal effect of ozone has been found to exceed that of chlorhexidine.<sup>6</sup>

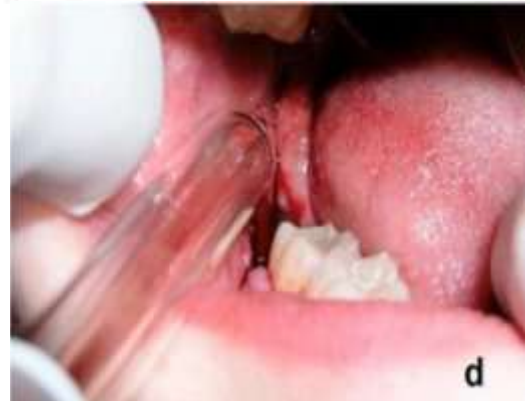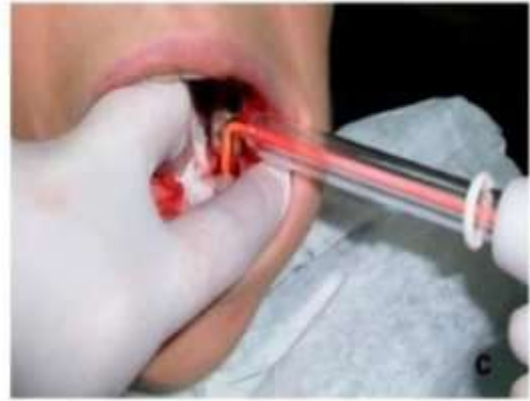### • Management of infectious lesions

#### ✓ Post-Extraction

After final debridement of the socket, irrigate with copious amounts of ozonated water and then use gauze imbibed with ozonated water to compress the extraction site. Before retiring the patient, fill the socket with ozonized oil and cover it with gauze will reduces the post-extraction healing time and complications by forming a pseudo-membrane over the socket, so protecting it from any physical and mechanical insults.<sup>58</sup>

It improves properties of erythrocytes and facilitates oxygen release in the tissues. This results vasodilatation and hence improves the blood supply to the ischemic zones. Exposure to medical grade ozone promotes more complete and rapid normalization of nonspecific resistance and T-cellular immunity.

The impact of ozone on epithelial wound healing in the oral cavity was observed by Filippi. It was found that ozone-water can be used daily to speed up the healing rate in the oral mucosa. This effect can be seen in the first two postoperative days.<sup>7</sup>



#### ✓ Post-Extraction Alveolitis

After thorough assessment, remove the necrotic plug and debris from the extraction site, irrigate with large amounts of ozonated water then fill the alveoli with ozonized oil. Antibiotic coverage may be indicated. Instruct the patient to apply ozonized oil 3-4 times a day until total healing.<sup>8</sup>

When surgical removal of bone sequestra is carried out, ozone can be used as an alternative to hyperbaric oxygen therapy. It also increases the phagocytosis performance of polymorphonuclear cells.<sup>6</sup>

Ozone therapy in the management of bone necrosis or in extraction sites in patients treated with Bisphosphonates may stimulate cell proliferation and soft tissue healing. It has been documented that dental extraction becomes possible in a patient with avascular bisphosphonate-related jaw osteonecrosis or in those who received pyrophosphate analogous when treated with ozone therapy.<sup>7</sup>

#### ✓ Surgical Procedures

Ozonated water can be used as an irrigant or as a final surgical site lavage. Cover the sutures with a thin layer of ozonized oil and instruct the patient to apply the oil 3-4 times a day.<sup>58</sup>

Ozone therapy was found to be beneficial for the treatment of the refractory osteomyelitis in the head and neck in addition to treatment with antibiotics, surgery and hyperbaric oxygen.<sup>2</sup>

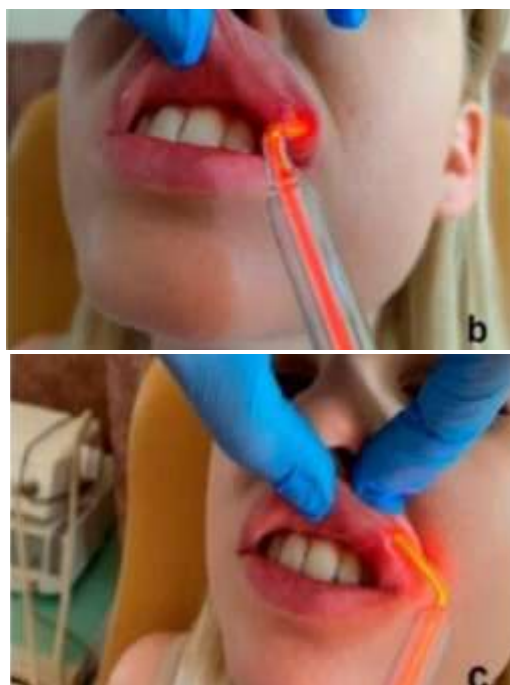Other soft tissue lesions like herpes, aphthous ulcer, cheilitis, candidiasis, cysts other traumatic wounds also show marked resolution owing to the healing capacity of ozone. However, no antiviral effects against Herpes simplex virus (HSV-1 and 2), Human Cytomegalo-virus (HCMV) and Epstein Bar virus (EBV) has been reported.<sup>6</sup>

#### ✓ Ozone Gas Application

Seal the affected area with a PVC or silicone cap and apply ozone gas for 1-2 minutes. Repeat if necessary. In case of cyst fistula, insert a plastic needle slowly in the passage of the fistula and inject 1-2 cc of ozone gas. Anesthesia might be indicated in this procedure.<sup>8</sup>

#### ✓ Ozonated Water Application

In situations of large traumatic wounds, burns



and cuts, the combined use of ozone gas and ozonated water are indicated. Prepare the ozonated water using Acquazone ozonated water column and irrigate for 10 minutes the affected area. In case of supra-infected lesions, use a strong preparation of ozonated water. During the healing phase, a mild solution is more appropriate.<sup>8</sup>

A potential antiseptic agent and the aqueous form showed less cytotoxicity than gaseous

ozone or established antimicrobials (chlorhexidine digluconate 2%, 0.2%; sodium hypochlorite- 5.25%, 2.25%; hydrogen peroxide 3%) under most conditions.<sup>6</sup>

#### ✓ Ozonized Olive Oil Application

These oils have a greater advantage over commonly used antiseptics and ointments due to their wide range of activities during all phases of the healing process.<sup>8</sup>

Ozonated oil applied on herpes labialis and mandibular osteomyelitis demonstrated faster healing times than conventional protocols. Ozone, neutralizes herpes virions by direct action, thus inhibiting bactericidal supra-infections, and stimulating the healing of tissues through circulatory prompting.<sup>4</sup>

#### ✓ Remineralization after Pediatric orthodontics

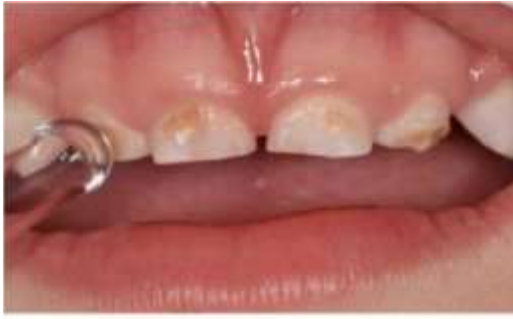The white spot lesions that are visible have been observed to appear 4 weeks after orthodontic treatment. Even though the enamel-bracket interface is the region that is most prone to the development of white spot lesions, microleakage can enter beneath the bracket. Enamel prevention is so crucial in orthodontics. Ozone can be utilized in such enamel lesions.<sup>5</sup>

Ghobashy et al. evaluate the effects of ozonized olive oil gel in reducing enamel demineralization around orthodontic bracket during orthodontic treatment. The use of ozonized olive oil gel in addition to the standard oral hygiene regimen was found to show significantly less decalcification of teeth among orthodontic patients. Due to its strong oxidizing effect, ozone might have negative effects on resin tooth adhesion related to the oxygen inhibition of polymerization. Cehreli SV et al. concluded that enamel pretreatment with ozone did not affect the shear bond strength of adhesive systems used for bonding.<sup>6</sup>

#### ✓ Early childhood caries

Dental caries is caused by an ecological niche of caries producing organisms. Much has been reported about the effectiveness of ozone in the elimination of carious lesions. This is attributed not only to the marked anti microbial properties of ozone but also to the fact that ozone oxidizes the pyruvic acid produced by the cariogenic bacteria to acetate and carbon dioxide.<sup>6</sup>



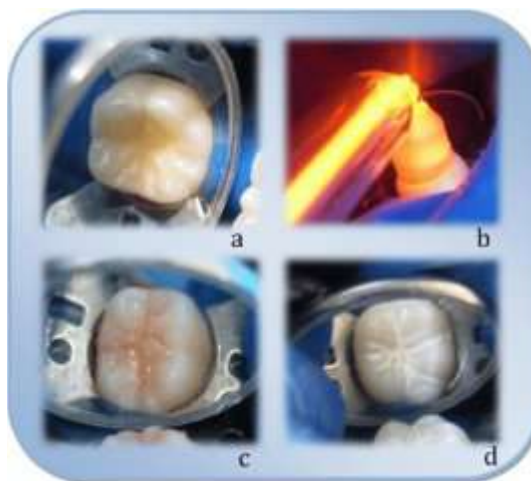


#### ✓ Pit and fissure sealants

Deep pits and cracks are challenging to clean, making it very probable that food will become lodged there and proliferate bacteria. In these situations, using ozone is very effective.<sup>4</sup> In cases of shallow lesions it penetrate about 1mm deep at the maximum.<sup>3</sup> It is advised apply a remineralizing product and seal the clean cracks after the ozone treatment.<sup>4</sup>

Ozone removes the smear layer leaving behind the exposed dentin that is occluded by the remineralizing agent applied. Huth et al. concluded that ozone application significantly improved non-cavitated initial fissure caries in patients at high caries risk over a 3-month period.<sup>6</sup>

The ozone unit must also be used correctly; the ozone cap must be held directly against the caries lesion allowing the ozone to penetrate the decay and biofilm. Where there is a cavitated 4mm deep root caries lesion adjacent to the gingival margin, simply using ozone treatment would probably not suffice. To manage this kind of a situation the outer caries must first be removed, leaving about 1 mm of caries over the cavity floor. Then the ozone treatment followed by routine restoration is indicated.<sup>3</sup>



#### ✓ Restorative dentistry

The American Academy of Paediatric Dentistry has said that "the objectives of restorative treatment are to repair or limit damage from caries, protect and preserve tooth structure, re establish adequate function, restore aesthetics (where applicable), and facilitate good oral hygiene."<sup>5</sup>

Tooth structure loss occurring due to multiple factors like attrition, abrasion, erosion, trauma from occlusion may cause wearing away of enamel and dentin thereby causing hypersensitivity. Gaseous Ozone application has been found to effectively reduce sensitivity of not only exposed enamel and dentin but also in cases of root sensitivity. 40-60 s application of ozone is found to instantly reduce pain in these sensitive teeth.<sup>6</sup>

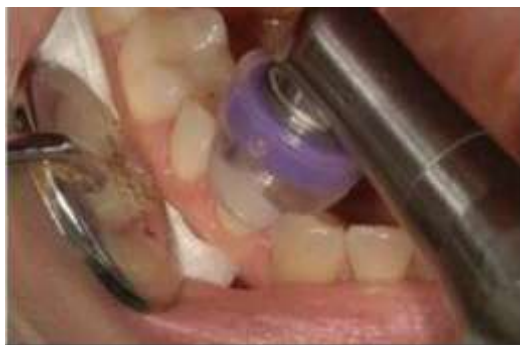Smear layer present over the exposed root surface prevents the penetration of calcium and fluoride ions deep into the dentinal tubules. Ozone removes this smear layer, opens up the dentinal tubules, broadens their diameter and allows the Calcium and Fluoride ions to flow into the tubules easily, deeply and effectively to plug the dentinal tubules, preventing the fluid exchange through these tubules. Thus, ozone can effectively terminate the root sensitivity problem within seconds and also results last longer than those by conventional methods.<sup>78</sup>

The efficacy of ozone in restorative dentistry and its effect on dental materials as prophylactic agent concluded that ozone gas can be applied prior to etching and the placement of sealant. The longer exposure to ozone gas has a strong bactericidal effect on microorganisms for extended period within the dentinal tubules of deep cavities, which could result in increasing the clinical success of restorations, with no negative impact on dentin and enamel shear bond strength of adhesive restoration.<sup>57</sup>

Ozone's oxygen atoms interact with bacteria that cause periodontal and dental problems by causing cavities in the teeth. By oxidizing dangerous microorganisms, oxygen destroys them and aids in the breakdown of the plaque biofilm. Since we have more antioxidants and scavengers than infections have, it does not harm healthy cells.

#### ✓ Root canal therapy

The aim of conventional root canal therapy is to provide a clean, shaped, root canal that facilitates the placement of an adequate root filling.



There may be multiple canals, frequently linked by a "web" of accessory canals. There is the so-called "apical delta" and the common lateral canals. Irrigants reaching these areas to disinfect and dissolve organic debris where it is impossible to instrument mechanically. When irrigating with the usual irrigant solution, for example sodium hypochlorite, ozone can be applied to the hypochlorite solution in the root canals. This technique allows the root canal system to be thoroughly disinfected and possibly be sterilized. In cases where previous root canal treatment has failed, *Enterococcus faecalis* seems particularly prominent and especially difficult to eradicate. Ozone will eliminate this bacterial type.<sup>7</sup>

Nagayoshi and colleagues found nearly the same antimicrobial activity (against *E. faecalis* and *Streptococcus mutans*) and a lower level of cytotoxicity of ozonated water as compared with 2.5% NaOCl.<sup>3</sup>

Muller et al., 2007 has also found 5% NaOCl superior to gaseous ozone in eliminating microorganisms organised in a cariogenic biofilm. Moreover, a recent study has found that the irrigation of infected human root canals with ozonated water, 2.5% NaOCl, 2% chlorhexidine and the application of gaseous ozone for 20 min was not sufficient to inactivate *E. faecalis*.<sup>1</sup>

Root canal pathogens like *Candida albicans*, *Peptostreptococcus microns*, and *Pseudomonas aeruginosa* have been proven to

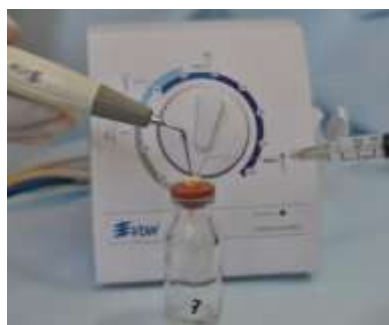be destroyed by ozone. As a result, it is utilised in endodontics as an intracanal irrigant encourages tissue regeneration and bone healing.<sup>6</sup>

Ozone is effective when it is prescribed in adequate concentration, time and delivered correctly into root canals after the traditional cleaning, shaping and irrigation has been completed. Intra canal gas circulation of ozone at a flow rate of 0.5–1 l/min with net volume of 5 gm/ml for 2–3 min showed encouraging results against pathogenic microbes in the root canal. Ozonated water can be used as an intracanal irrigant and in infected necrotic canals, ozonized oils can be used as an intra-canal dressing reducing the marked anaerobic odor emanating from infected teeth.<sup>6</sup>

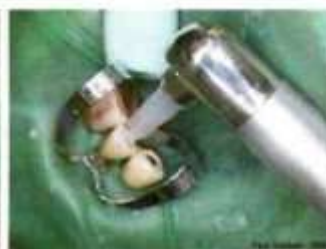After final shaping and cleaning of the canal(s), adapt a 25-27 G needle on the delivering central tip of the handpiece, making sure not to obliterate the free gas circulation inside the round tapered housing. Cut a piece of PVC or silicone Tube according to the clinical situation in order to seal the access cavity with the needle inside the canal. The needle should not block the intra-canal gas circulation towards the canal orifice. Fill the canal with saline or distilled water and apply ozone for 2-3 minutes per canal at Sug/ml, 0.5 - 1Llmin flow rate. During the canal shaping and irrigation, ozonated water can be used as a disinfectant and irrigant.<sup>8</sup>

In some situations, there is a need to disinfect the root canal system with a temporary dressing until the symptoms are relieved and the canal(s) are ready to be filled. Follow the same protocol as above and use ozonized olive oils as a temporary disinfection dressing. Fill a Icc disposable syringe with the oil and adapt a 25G needle. Insert the needle as deep as possible inside the canal and inject slowly while retrieving the needle slowly out of the canal. Also can use a Lentulo to fill the canal with the ozonized oil.<sup>8</sup>

In maxillary peri-apical lesions, ozone infiltration is performed the same way you give a local



*An adapted silicone cap and 25G needle for ozone gas canal disinfection*



*In case a silicone cap is unpractical put the suction tip close to the canal orifice*

anesthetic injection on the buccal side. Depending on the size and severity of the lesion, the concentration varies between 5 and 10 µg/ml at a volume of 1-3 cc. Inject the gas very slowly as close as possible to the site of the lesion. Repeat the infiltration once a week until resolution of the symptoms."

In mandibular peri-apical lesions, the use of an intraosseous needle to deliver the ozone gas right into the bone is indicated. Use your preferred technique to perforate the cortical bone, making sure to stay away of the alveolar inferior canal and mental nerve. The access point is usually 2-3 mm under the free gingival level where the cortical bone is easily perforated. Inject very slowly as described above.<sup>8</sup>

In peri-apical lesions, ozone gas infiltration contributes in the nonsurgical management of these lesions. Siqueira and colleagues<sup>14</sup> evaluated the antibacterial activity of the ozonated oil and calcium hydroxide pastes against bacterial species commonly associated with the etiology of periradicular diseases. Of the tested medicaments, ozonated oil was the most effective against the evaluated bacterial species.<sup>3</sup>

It is also postulated that ozone will penetrate through the apical foramen, and enter into the surrounding and supportive bone tissue. The effect of ozone on these tissues will be to encourage healing and regeneration.<sup>7</sup>

#### ✓ Avulsion

Ozone can be utilised to disinfect the avulsed tooth because it has broad-spectrum antibacterial activity in water and is biocompatible with human oral epithelial cells and gingival fibroblast cells.

A high level of biocompatibility of aqueous ozone on human oral epithelial cells, gingival fibroblast cells, and periodontal cells has been found. 2 minute irrigation of teeth with non-

isotonic ozonated water not only provides mechanical cleansing, but also decontaminates the root surface, with no negative effect on periodontal cells on the tooth surface.<sup>6</sup>

#### ✓ Others

Ozone application was found to remove the toothbrushes bristles microbiota following conventional brushing.<sup>36</sup>

Ozonated water effective for killing gram positive and negative oral microorganisms and oral candida albicans.<sup>5</sup>



Bezirtzoglou et al. isolated various species of Streptococcus species, Aerococcus viridians, C. albicans, S. aureus and Staphylococcus epidermidis from toothbrushes of children. They observed maximum decontamination efficacy of ozone treatment against toothbrush bristles microbiota after 30 min while exposure for short time periods seems to be ineffective.<sup>6</sup>

Ozonated water can be used to purify dental unit water lines and reduce crossinfection.<sup>5</sup>

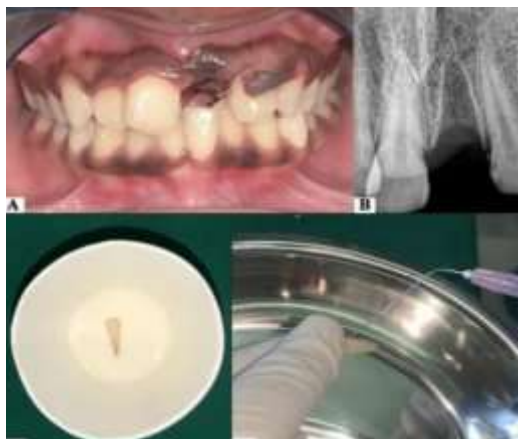In dental unit water lines, ozone achieved a 57% reduction in biofilm and a 65% reduction in viable bacteria in spite of a very low dosage and short time of application.<sup>23</sup>

Ozonated water can be used as a cold disinfection solution for medical and dental instruments, as well as for cabinets, countertop disinfection, hands wash disinfectant solution, fiber optic tips, contact lenses, surgical loupes lenses, etc.<sup>8</sup>

gaseous ozone can be clinically used for disinfection of pediatric orthodontic appliances.<sup>4</sup>

### The Benefits of Ozone Dental Treatment<sup>8</sup>

- Simple treatment Completely pain free procedure
- Eliminates damage and unnecessary tooth reduction since there is no drilling.
- Eliminates the use of anesthesia
- Kills 99% of bacteria in cavities





- Excellent for nervous or anxious patients
- Produce huge financial gains for the dental practitioner, in terms of increased income, reduced time, reduced failure, and enhanced 'professionalism'.

## Ozone Toxicity

Several ill effects, including epistrophe, upper respiratory tract irritation, coughing, rhinitis, headache, sporadic nausea, breathlessness, blood vessel enlargement, vomiting, poor circulation, heart issues, and occasionally stroke, have been linked to the inconsistent use of ozone. The tremendous oxidant capacity of ozone necessitates proper ozone hygiene. It is crucial to properly scavenge the surplus ozone gas and stop it from leaking into the office setting. All materials that encounter the gas must be ozone resistant, such as glass, silicon, and Teflon, due to ozone's tremendous oxidative power. The patient must be put in the supine position and treated with vitamin E and n-acetylcysteine in the event of ozone intoxication.<sup>5</sup>

Exposure of 0.1-1umol/mol produces headaches, burning eyes, irritation to the respiratory passage. Even low concentration of ozone in air are very destructive to organic materials such as latex, plastic and animal lung tissues.<sup>7</sup>

Ozone is beneficial to dentistry, but it should not be used by people with certain medical conditions, including pregnancy, Glucose-6-phosphate dehydrogenase deficiency (favism), recent myocardial infarction, hyperthyroidism, severe anaemia, severe myasthenia, haemorrhage, acute alcohol intoxication, and ozone allergy.<sup>5</sup>

## Conclusion

The applications of ozone therapy in a pediatric practice rely mainly on the fact that ozone application is a very quick, effective, easy and especially a painless procedure to perform. These aspects of the treatment not only enhance the operator efficiency but also effectively improves the patient compliance and tolerance to the treatment procedure. Attaining a positive rapport with a child patient is the key to a successful pediatric treatment which can be very effectively accompanied by using ozone therapy.<sup>4</sup>

Its atraumatic, painless, non invasive nature and relative absence of discomfort increase patient's acceptability and compliance thus making it an ideal treatment choice specially for pediatric patients.<sup>7</sup>

## REFERENCES

1. Review The application of ozone in dentistry: A systematic review of literature Amir Azarpazhooh a, \*, Hardy Limeback
2. OZONE IN PEDIATRIC DENTISTRY: A MIRACLE THERAPY Dr. Krunal S. Soni\*, Satabdi Saha\*, Dr. Niharika\*\*, Prof (Dr.) Subrata Saha\*\*\*
3. OZONE IN PEDIATRIC DENTISTRY- A REVIEW Dr. Sourabh Ramesh Joshi 1 , Dr Sreyashi Gupta2 , Dr Mohammed Muzammil Khan3 , Dr. Vidhya Vijayan4 , Dr. Deepthi Nirmal Gavarraju5 , Dr. Rahul VC Tiwari6DOI: 10.47750/pnr.2022.13.S09.345
4. Review Article Ozone in Dentistry- A review Dr. Ruhpreet Kaur Sandhu B.D.S., Genesis Institute of Dental Sciences and Research Ferozepur Punjab, India
5. Ozone: An underrated tool in pediatric dentistry Dr. Apurva Laxman Mahale, Dr. Dinesh Rao, Dr. Sunil Panwar, Dr. Kritika Samaddar and Dr. Remi RV
6. Dental applications of ozone therapy: A review of literature Sansriti Tiwari a\*, Alok Avinash a, Shashank Katiyar b, A. Aarthi Iyer c, Suyog Jain d. <http://dx.doi.org/10.1016/j.sjdr.2016.06.005>
7. OZONE - A NEW REVOLUTION IN DENTISTRY. Aditya Sharma1 , Shaista Suhail1 , Shaleen Chandra 1 , A. P. Tikku 2, O. P Gupta3 , Shalini GuptaVol 4, Issue 10, 2015.
8. Ozone Therapy In Dentistry.vol:4 issue 2 CODS -Sep 202
9. Review Potential Clinical Applications of Ozone Therapy in Dental Specialties-A Literature Review, Supported by Own Observations Izabela Barczyk etal. Int. J. Environ. Res. Public Health 2023, 20, 2048. <https://doi.org/10.3390/ijerph20032048>



# MANAGEMENT OF PREGNANT PATIENT IN ORTHODONTIC PRACTICE

## Authors:

Nisha C Joseph<sup>1</sup>

Dhanya M<sup>2</sup>

Binnoy Kurian<sup>3</sup>

Post Graduate<sup>1,2</sup>

Department of Orthodontics and  
Dentofacial Orthopaedics  
St Gregorios Dental College

Professor and Head<sup>3</sup>

Department of Orthodontics and  
Dentofacial Orthopaedics  
St Gregorios Dental College

## ABSTRACT

In the recent times, the number of adult patients seeking orthodontic treatment have grown because of increase in awareness. In these adult patients, there are many pregnant females coming to orthodontist for treatment or a lady getting pregnant during the treatment. 'Can a pregnant woman continue with orthodontic treatment or can she start with orthodontic treatment during pregnancy?' This is a difficult question to answer but 'Yes', pregnant women can go for orthodontic treatment but with precautions. Present article gives us the information how to go about the treatment in pregnant women, the precautions to be taken, effect of drugs and hormonal changes on orthodontic treatment.

**Keywords:** Pregnancy, Orthodontist role, Pregnancy gingivitis, Tooth movement, Hormones.

J Ind Dent Assoc Kochi 2024;6(2):17-23.

## INTRODUCTION

The demand for esthetics and orthodontics has influenced majority of young population over the years and most of them are women. The orofacial region is usually an area of significant concern especially for women because it draws attention at social gatherings. Several times, women undergoing orthodontics treatment announce their pregnancy during mid-treatment or at times women seeking orthodontic treatment might be planning their pregnancy within the treatment duration. Pregnancy is a special phase in a woman's life, demanding numerous emotional, physiological, psychological, and lifestyle changes. Hence, an orthodontist has to take call on whether to continue the treatment by taking all the precautionary measures and educating the patient regarding the importance of oral hygiene or to delay the treatment until postpartum depending on several factors.

Certain factors to be kept in mind before going ahead with braces in pregnant women are:

1. Pregnancy associated gingivitis.
2. Hormonal changes and its effect on tooth movement.
3. Food habits and craving during pregnancy and its effect on orthodontic treatment.
4. Effect of drugs in pregnancy and orthodontic movement.

## GINGIVAL HEALTH AND PREGNANCY

Gingivitis is caused by several known systemic and local factors. Among systemic factors, the role of hormonal changes during pregnancy is well-established.<sup>1</sup> While presence of fixed orthodontic appliances alone may not cause gingivitis factors, such as pregnancy and poor oral hygiene combined together could precipitate acute gingival inflammation that may progress to a poor periodontal condition in a patient receiving orthodontic therapy.<sup>2</sup>

Gingivitis and gingival hyperplasia have been associated with hormonal changes as seen during puberty, pregnancy and menopause. Studies have shown that pregnant women have an increased incidence of gingival inflammation compared with nonpregnant women. Progesterone has been shown to increase

gingival exudates, affect the gingival vascularity and integrity of the capillary endothelial cells.<sup>3</sup> Sex hormone-induced alterations in the subgingival microflora led to an increase in periodontal inflammation.<sup>4</sup>

During pregnancy, there could be immunosuppression where CD4:CD8 ratios may be decreased and there could also be low lymphocyte responsiveness.<sup>5</sup> The presence of increased sex hormones during pregnancy may cause epithelial separation and an increase in vascular permeability. Vascular and hormonal changes may increase the gingival crevicular fluid and aggravate response to plaque.<sup>6</sup> It is known that fixed appliances can act as plaque-retaining devices. However, when coupled with preexisting gingival inflammation that may be present in a pregnant patient, there could be fast progression toward periodontal disease. There is also an additional factor of self-neglect among pregnant women. Thus, it is of paramount importance to create awareness in the dental profession and also to educate women about the importance of oral health care during orthodontic therapy especially if they are pregnant.

## PREGNANCY EPULIS

Occasionally, a severe swelling is observed in the gingiva of pregnant women which is known as pregnancy tumour or epulis. It is a non-neoplastic and fibrous granulomatous lesion that develops during 3rd month of pregnancy or even at earlier phase due to the vascular response caused by the increased progesterone usually in patients with existing gingivitis.<sup>7</sup> It may subside following the delivery of the child if the lesion is small but large lesions may require surgical excision in severe cases.<sup>8</sup> During the orthodontic treatment, if proper hygiene is maintained and regular oral prophylaxis, this condition could be kept under control.

## EFFECT OF HORMONES ON TOOTH MOVEMENT

Eva Hellsing and Lars Hammarström did experiments in rats indicated that the velocity of orthodontic tooth movement is influenced by hormones as well as trace elements. Orthodontic movement occurs faster in preg-

nant rats compared with nonpregnant rats. Hua Xi Kou Qiang Yi Xue Za Zhi. 1998 studied the effect of progesterone on orthodontic tooth movement. He found that progesterone influences the periodontal reconstruction on orthodontic tooth movements in pregnant rats and may be helpful in alveolar bone formation.<sup>9</sup> Longterm progesterone administration could reduce the rate of tooth movement.<sup>10</sup> Estrogen results in decreasing the rate of bone resorption. Estrogen inhibit the production of various cytokines, mainly interleukin - (IL-1), (TNF- ) tumor necrosis factor - alpha, and interleukin - 6 (IL-6), which are involved in bone resorption by stimulating osteoclast formation and osteoclastic bone resorption. Thus, estrogens decrease the velocity of tooth movement.<sup>11</sup>

Relaxin has been known as a pregnancy hormone. It is released just before child birth to loosen the public symphysis, so that the relaxed suture will allow widening of the birth canal for parturition. Relaxin influence on soft tissue remodeling and several mediators that stimulate osteoclasts formation. Administration of relaxin might accelerate the 2early stages of orthodontic tooth movements. Relaxin might be used as an adjunctant to orthodontic therapy, during or after tooth movement, for promotion of stability, for rapid remodelling of gingival tissue during extraction space closure, for orthopaedic expansion in nongrowing patients, by reducing the tension of the stretched soft tissue envelope, particularly the expanded palatal mucosa, after orthognathic surgery.<sup>12</sup>

## VARIOUS CONDITIONS ASSOCIATED WITH PREGNANCY

Pregnant women are susceptible to oral conditions such as tooth mobility, gingival inflammation, dental caries, and other conditions; hence, appropriate preventive oral health care could reduce the following conditions and the pain associated with them. A higher prevalence of dental pain has been revealed in pregnant patients indicating a need for proper oral healthcare services. In a study conducted in 2014, over half of the pregnant women reported dental pain whereas only 28% of the women opted for dental care. They reported that harmful stimulation of pulp tissue by the influence

of hormonal changes on the pulp might lead to pain.<sup>13</sup> Before continuing the treatment, it is advisable to consult the patient's obstetrician if any known complications are to be expected. History of current drugs and their possible side effects should be taken into consideration that might alter the course of orthodontic therapy. Drugs such as vitamin D could probably cause a reduction in tooth movement during the orthodontic treatment.

Detailed patient history, medical conditions, and previous pregnancy-associated complications if any should be taken into account in advance before initiating orthodontic treatment. It is always advisable to wait until postpartum in patients with a previous medical and dental history related to pregnancy-associated complications. A thorough dental history of the patient's attitude toward dental hygiene should be assessed. Oral conditions associated with mobility of teeth, caries, and periodontal pockets should be taken into consideration. A simple and least painful treatment should be planned for pregnant patients. Light orthodontic forces can be given.<sup>14</sup> When a radiographic study is needed for appropriate management of a pregnant patient; the American College of Radiology recommends that "Healthcare workers should tell patients that x-rays are safe and provide patients with a clear explanation of the benefits of x-ray examination." According to the American College of Radiology, "No single diagnostic procedure results in a radiation dose that threatens the well-being of the developing embryo and foetus."

According to America's National Council on Radiation Protection, "foetal risk is considered to be negligible at 5 rad or less when compared to the other risks of pregnancy, and the risk of malformations is significantly increased above control levels only at doses above 15 rad." Exposure below 5 rad has not been associated with an increase in foetal anomalies on pregnancy loss and a single diagnostic radiographic procedure very early in prognosis does not harm a developed pre-embryo or embryo. A panoramic study causes about one-third of the radiation exposure associated with a full-mouth series with an E-speed film and a rectangular collimated beam. This can be further reduced using a lead apron over the abdomen and thyroid collar.<sup>15</sup> (Figure1)

Estimated foetal exposure from a single diagnostic radiograph is 0.0001 rad. Diagnostic x-rays during pregnancy are considered safe, yet physicians should use reasonable caution while remaining sensitive to patients' fear and concerns. A physician's caution should not become unreasonable. The exposure management of the pregnant patient in most situations should not place the foetus at increased risk. The most sensitive time for radiation effects on a foetus is between the 32nd and 37th day (approximately 4.5-5.5 weeks) of gestation since this is the time for organogenesis. The developing foetus must be in a direct pathway of radiation which is unlikely to occur during dental radiographs; hence, dental radiographs should not be contraindicated if there is a potential benefit to be gained. Physiological changes during pregnancy are frequent and require immediate attention.

Pre-existing or chronic hypertension and gestational hypertension occur in 12-22% of pregnant women. Prenatal care providers should be consulted before initiating dental procedures in women with hypertension to classify the type of severity of hypertension and to rule out pre-eclampsia if indicated.<sup>16</sup> Meticulous control to avoid or minimize dental infection is important for pregnant women with diabetes. During the second and third trimesters, a decrease in blood pressure and cardiac output can occur while the patient is in a supine position. It occurs due to the decrease in venous return to the heart from the compression of the inferior vena cava by the gravid uterus, which can result in a reduction in cardiac output. To prevent supine hypotensive syndrome in the dental chair, the pregnant woman should have the right hip elevated 10-12 cm, or placing the patient in a 5-15% tilt on her left side can relieve the pressure, a full left lateral position may be needed. Pregnant women have delayed gastric emptying and are always considered to have a "full stomach." Pregnant patients at times develop moderate hypoxemia and some develop abnormal alveolar-arterial oxygen gradient when placed in the supine position. Ventilation patterns and patient position must be adjusted for the pregnant patient to avoid hypoxemia. Morning sickness also increases the risk of aspiration and vomiting due to the patient's enhanced gag reflex and decreased



Figure1:  
Thermoluminescent dosimeter (TLD)  
in radiology apron.

gastric emptying. Orthodontic treatment is not contraindicated in pregnant patients undergoing delivery under general anaesthesia, but it is advisable to plan orthodontic treatment in such a way that orthodontic braces should be removed before electing for surgical procedures under general anaesthesia to avoid any complications due to insertion of oral tubes in the operation theatre. During the 8 months of pregnancy, the fixed orthodontic appliances should be removed and a temporary removable appliance such as Hawley's, wrap around retainers or Essix retainer could be delivered to hold the corrected dentition and fixed appliances could be continued during the postpartum period.

Premature labour can be faced while treating a pregnant patient and may be characterized by back discomfort, pelvic, and abdominal pressure or vaginal discharge. Premature labour signs should be taken seriously. Furthermore, short-term appointments should be given to the patients during the third trimester. Drugs during pregnancy: There are a small number of drugs in dentistry that are teratogens or are contraindicated during pregnancy, it is always advisable to consult the gynaecologist before prescribing medication.<sup>17</sup>

## MANAGEMENT OF ORAL HEALTH IN PREGNANCY WITH BRACES

In case of pregnancy, it is important to get the opinion of the gynaecologist, if any known complications are to be expected. A complete dental history provides the orthodontist knowledge about the patient's attitude toward dental care and patient's priorities. A patient who does not receive routine dental care and is negligent about oral care is unlikely to be compliant during orthodontic treatment. As the number of adult patients seeking orthodontic treatment is on an increase, it is important that the orthodontists must be more active and capable of diagnosing gingival and periodontal problems. If the patient already has signs, such as gingival inflammation, bleeding on probing, presence of pockets and poor oral hygiene, it may be wise to start orthodontic therapy after the pregnancy.

However, there are no obvious contraindications to orthodontic therapy in a healthy pregnant patient. However, it may be advisable to limit the visits to shorter appointments to avoid the patient being in extreme supine position especially during the later stages of the pregnancy. Radiographic imaging, such as a panoramic film and periapical films are routinely used to assess periodontal health and root inclinations. According to American Dental Association (ADA), every precaution should be taken to minimize radiation during pregnancy. It is important for the orthodontist to know, if the patient is self-motivated and enthusiastic about receiving orthodontic treatment. It is especially important to take into account the hormonal and physiological changes that will be anticipated during the course of pregnancy and the patient must be mentally prepared to visit the orthodontist for regular adjustments. It is critical to discuss in depth about the entire course of the treatment, the expected number of visits and the level of cooperation that will be required for successful completion of orthodontic treatment to achieve ideal function and aesthetics.

## DRUGS DURING PREGNANCY AND ORTHODONTIC TREATMENT

A history of current medications is also valuable because various drugs have oral side effects and may influence the course of the orthodontic therapy. Drugs, such as bisphosphonates and vitamin D metabolites could probably cause a reduction in tooth movement during orthodontic therapy, while nonsteroidal anti-inflammatory drugs have also been shown to reduce bone resorption.<sup>18</sup> Any previous medical conditions such as diabetes mellitus or previous pregnancy complications are important to know in advance before starting orthodontic treatment. If the patient has suffered previously from certain complications during her pregnancy and is at a risk as per her medical care provider, it may be best to wait until postpartum to start orthodontic therapy.<sup>19,20</sup>

## ROLE OF PROFESSIONALS

For successful completion of orthodontic treatment, a good communication must be established between the patient and the orthodontist from the beginning. In addition to reinforcing oral hygiene, it is important that the patient is sent for professional cleaning at regular intervals. Good communication among health care professionals also benefits the patient and improves their quality of life.

## ROLE OF PATIENT

It is important for women to be aware of the importance of oral health care especially during pregnancy. We have therefore described in detail the known associations between periodontal disease and complications during pregnancy. Simple and effective home-care measures described earlier and professional dental care will enable women to prevent any gingival and D or periodontal issues during the course of their orthodontic treatment. Pregnancy, as such is not a contraindication for orthodontic treatment. Care should be taken to minimize the potential exaggerated inflammatory response related to pregnancy-associated hormonal alterations. Meticulous plaque control and oral hygiene should be maintained during treatment.



Avoid X-rays or drug therapy and extractions particularly in the first trimester. The second trimester is the safest time to perform treatment. Avoid supine position in late pregnancy. Supine hypotensive syndrome may occur due to obstruction of the vena cava and aorta. This may result in reduction in return cardiac blood supply with decreased placental perfusion. This can be prevented by placing the patient on her left side or simply by elevating the right hip 5 to 6 inches during treatment. Appointments should be short, and the patient should be allowed to change positions frequently. A fully reclined position should be avoided if possible. However, long, stressful appointments and surgical procedures should be delayed until the postpartum period. Analgesics, antibiotics, local anaesthetics, and other drugs required during pregnancy should be reviewed for potential adverse effects on the foetus.

## CONCLUSION

From literature review and case report, it has been found that orthodontic treatment during pregnancy may aggravate gingivitis caused by local and systemic factors. Periodontitis during pregnancy may lead to complications during pregnancy and preterm low-birth-weight babies. Awareness among oral and prenatal health care professionals is critical for optimal patient care. Preventive dental measures such as frequent checkups, oral health examinations, and updates regarding medical records and consultations with the gynaecologist may aid in smooth orthodontic therapy during the pregnancy. A clear aligner could be a great tool for orthodontics in pregnant women. Further research is required regarding the use of aligners in pregnancy-associated orthodontics.

## REFERENCES

1. Hua Xi Kou Qiang, Yi Xue Za Zhi. Effects of pregnancy on orthodontic tooth movements: Effects of progesterone on orthodontic tooth movements in pregnant rats 1998 May;16(2):124-26.
2. Loe H, Silness J. Periodontal disease in pregnancy. I. Prevalence and severity. *Acta Odontol Scand* 1963; 21:533-51.
3. Pankhurst CL, Waite IM, Hicks KA, Allen Y, Harkness RD. The influence of oral contraceptive therapy on the periodontium – duration of drug therapy. *J Periodontol* 1981; 52:617-20.
4. Kornman KS, Loesche WJ. The subgingival microbial flora during pregnancy. *J Periodontal Res* 1980; 15:111-22.
5. O'Neil TC. Maternal T-lymphocyte response and gingivitis in pregnancy. *J Periodontol* 1979; 50:178-84.
6. Lindhe J, Branemark PI, Lundskog J. Changes in vascular proliferation after local application of sex hormones. *J Periodontal Res* 1967.
7. Hall EJ. Scientific view of low-level radiation risks. *Radiographics* 1991; 11:509-18.
8. Sirisoontorn I, Hotokezaka H, Hashimoto M, Gonzales C, Luppapornlarp S, Darendeliler MA, et al. Tooth movement and root resorption; the effect of ovariectomy on orthodontic force application in rats. *Angle Orthod* 2011; 81:570-7.
9. Hua Xi Kou Qiang, Yi Xue Za Zhi. Effects of pregnancy on orthodontic tooth movements: Effects of progesterone on orthodontic tooth movements in pregnant rats 1998 May;16(2):124-26.
10. Poosti M, Basafa M, Eslami N. Progesterone effects on experimental tooth movement in rabbits. *J Calif Dent Assoc* 2009 Jul;37(7):483-86.
11. Sirisoontorn I, Hotokezaka H, Hashimoto M, Gonzales C, Luppapornlarp S, Darendeliler MA, Yoshida N. Tooth movement and root resorption; the effect of ovariectomy on orthodontic force application in rats. *Angle Orthod* 2011; 81:570-77. Epub 2011 Mar 1.
12. Stewart DR, Sherick P, Kramer S, Breining P. Use of relaxin in orthodontics. *Ann NY Acad Sci* 2005 May; 1041:379- 87.
13. Krüger MS, Lang CA, Almeida LH, Bello-Corrêa FO, Romano AR, Pappen FG. Dental pain and associated factors among pregnant women: An observational study.

Matern Child Health J 2015; 19:504-10.

14. Almobarraz R. Orthodontic treatment and considerations during pregnancy. *Int J Med Dent* 2019; 23:523-26.
15. Suri V, Singla R, Suri V. Oral health care in pregnancy: A review. *J Adv Med Dent Sci Res* 2017; 5:9.
16. Kloetzel MK, Huebner CE, Milgrom P. Referrals for dental care during pregnancy. *J Midwifery Womens Health* 2011; 56:110-7.
17. Moore PA. Selecting drugs for the pregnant dental patient. *J Am Dent Assoc* 1998; 129:1281-6.
18. Bartzela T, Türp JC, Motschall E, Maltha JC. Medication effects on the rate of orthodontic tooth movement: A systematic literature review. *Am J Orthod Dentofacial Orthop* 2009 Jan;135(1):16-26.
19. Gameiro GH, Pereira-Neto JS, Magnani MB, Nouer DF. The influence of drugs and systemic factors on orthodontic tooth movement. *J Clin Orthod* 2007 Feb;41(2):73-78.
20. Jan Lindhe, Bertil Sonesson. The effect of sex hormones on inflammation. *Journal of Periodontal Research* 1967 Feb;2(1): 7-12.

# AI IN ENDODONTICS; WHERE ARE WE NOW?

## ABSTRACT

Artificial intelligence (AI) encompasses a broad spectrum of emerging technologies that continue to influence daily life. The evolution of AI makes the analysis of big data possible, which provides reliable information and improves the decision making process. (To mention the referred article) In medicine and dentistry, deep learning approaches have improved diagnostics, outperforming clinicians in accuracy and efficiency. This study aimed to provide information on endodontists knowledge and perceptions regarding AI.

**Methods:** A questionnaire was used to study the views of endodontists on AI use in clinical practice.

**Results:** In total, 83 questionnaires were answered and assessed. Most of the respondents rated their knowledge of AI as average (58.3%) above average (25%) or very poor (8.3%). The majority of the participants expected AI to impact their profession within 5 years (66.7%), with almost half of them (49%) predicting a positive impact. Among the most serious concerns were the responsibility for machine errors in unexpected situations (36.4%).

**Conclusions:** Within the limitations, this study emphasize the need for an additional education in this area to reduce negative attitudes towards AI.

**Keywords:** artificial intelligence; machine learning; qualitative research; clinicians' survey; perception; endodontists.

## Authors:

Akhila Surendran<sup>1</sup>  
Vishnuraj P R<sup>2</sup>

<sup>1</sup>PG Student  
Department of Conservative Dentistry  
and Endodontics, Sree Anjaneya Institute  
of Dental Sciences, Modakkallur  
Kozhikode, Kerala - 673315

<sup>2</sup>Raj Dental Clinic  
Veekshanom Road  
Ernakulam-682035



## INTRODUCTION

In general, artificial intelligence (AI) refers to the concept of automated machines able to perform human tasks. AI is a fast-paced developing field, with many applications already being available for use in our daily life activities (e.g., speech-/text-recognition, email spam-filters) and emerging uses attracting a great deal of attention in Medicine and Dentistry over the past decade.<sup>1,2</sup>

Functional applications of AI in dentistry include assisted treatment planning, computer aided diagnosis based on medical images and predictive data analytics.<sup>3</sup> In endodontics, it provide new solutions that facilitate the decision-making process of endodontist and can lead to decisions that minimize the failure of endodontic treatments and retreatments.<sup>4</sup> Furthermore, they permit decreasing the time spent on tasks and the number of cases of missed findings, and they prevent over treatment.<sup>5</sup>

The debate over sensitive data, privacy security and ethical concerns remains present in the research, public, political and industrial sectors. The uncertainty of the responsibility for machine errors and the currently vague guidelines require policymakers and medical professionals to seek legal clarification.<sup>6</sup> A pessimistic view of AI is that AI will replace humans in many industries. Recent news reports revealed that patients would follow AI advice over a doctor's advice about their cancer treatment in a country like Korea.<sup>7</sup> The misperception of AI might result in unsubstantiated concerns. So far, most studies investigated the perception of AI for medical professionals, radiologists and dentistry (dental) students, but only a few focused on endodontists inside India.

This study aimed to investigate endodontists' knowledge and perceptions regarding AI. Giving professionals from the state of Kerala, the opportunity to indicate the necessary steps for the introduction of AI in clinical settings is important in the context of coordinating a comprehensive educational program.

## METHODS

A 23-item questionnaire (Table A) was used, adapted from the survey design by Scheetz et

al.<sup>8</sup>, who validated the survey through a literature review and consultation with medical specialists. An electronic survey was designed using Google Forms. The survey was administered online through a mobile phone invitation (to mention the Main article for methodology). Demographic and professional information on the endodontists were obtained and questions concerning AI related knowledge, potential impact, expectations, advantages and concerns were included. Invitations were sent to a random sample of 100 endodontists. Participants were informed about the goal of the survey (medical research) in the preface of the questionnaire. By voluntarily participating in the survey after being given adequate information on its purpose, informed consent was implied.

Sample size estimation and power calculation were waived. This study was purely explorative and observational without concrete hypothesis testing. This prospective anonymous online survey was conducted between October 2023 and December 2023 in the state of Kerala.

**Statistical Analysis** The descriptive statistical analysis was performed on SPSS Version 28.0 (IBM, Armonk, NY, USA). A two-sided chi-square test or two-sided Fischer's test was used to calculate group differences. The level of significance was set at  $P \leq 0.05$

### Table A - Questions asked in the online survey regarding artificial intelligence (AI) among endodontists

#### How old are you?

- I. 26-35
- II. 36-45
- III. 46-55
- IV. >56

#### Gender?

#### Work environment-

- I. Rural
- II. Urban
- III. Somewhat rural
- IV. Somewhat urban

#### How often do you use artificial intelligence in your daily work?

- I. Never
- II. Monthly
- III. Weekly

**In comparison to your colleagues how would you rate your knowledge in the topic of AI and it's application possibilities in your profession?**

- I. Excellent
- II. Above average
- III. Average
- IV. Below average
- V. Very poor

**How long will it take in your opinion until AI has a noticeable impact on your profession?**

- I. 10 years
- II. never

**What degree of error tolerance is acceptable for AI based model that is used for disease screening by non-specialized health workers?**

- I. Equivalent to the worst performing
- II. Equivalent to the average performing
- III. Superior to the average performing
- IV. Equivalent to the best-performing
- V. Superior to the best-performing

**Can you imagine implementing the following workflow in your clinical life? Radiographs of a patient are diagnosed by an AI. A specialist evaluates the radiographs and the AI's findings.**

- I. Yes
- II. No
- III. Not sure

**Which of the following advantages regarding the application of AI in clinical life are most important?**

Evaluate from 1-5 (1 = least significant, 5 = most significant)

- I. Better access to disease-screening
- II. More targeted referrals
- III. More cost-efficient healthcare
- IV. Better diagnostics
- V. Less time-consuming monotonous tasks
- VI. More consistent diagnostics
- VII. More individual and evidence-based treatment

VIII. Better prediction of the course of disease

**Which of the following aspects are the most concerning regarding the application of AI in clinical life? Evaluate from 1-5 (1 = most concerning, 5 = least concerning)**

- I. Concerns regarding the outsourcing of the steps of procedure to large data and technology
- II. Companies Privacy and data security concerns
- III. Concerns over accountability and responsibility in case of machine errors
- IV. Lack of trust in the diagnostic capability of the AI
- V. Reduced demand for specialist groups
- VI. Challenges for the patient-doctor relationship
- VII. Concerns regarding the benchmarking between clinicians and AI
- VIII. Consequences for the workforce

**To what extent do you agree with the following statement: The introduction of AI will lead to improvement in my profession."**

- I. Strongly agree
- II. Agree
- III. Neither agree or disagree
- IV. Disagree
- V. Strongly disagree

**Artificial intelligence will revolutionize endodontics.**

- i. Agree entirely
- ii. Rather agree
- iii. Rather disagree
- iv. Disagree entirely

**These developments frighten me**

- i. Agree entirely
- ii. Rather agree
- iii. Rather disagree
- iv. Disagree entirely

**These developments make endodontic diagnosis more exciting to me**

- i. Agree entirely

- ii. Rather agree
- iii. Rather disagree
- iv. Disagree entirely

**Artificial intelligence should be part of medical training**

- i. Agree entirely
- ii. Rather agree
- iii. Rather disagree
- iv. Disagree entirely
- v. N/A

**Do you agree that AI has useful applications in the endodontic field?**

- I. Strongly agree/agree
- II. Neither disagree nor agree
- III. Strongly disagree/disagree

**Do you agree that the diagnostic ability of AI is superior to the clinical experience of human doctors?**

- I. Strongly agree/agree
- II. Neither disagree nor agree
- III. Strongly disagree/disagree

**Do you agree that you will always use AI to make medical judgments in the future?**

- I. Strongly agree/agree (=always/often)
- II. Neither disagree nor agree (=occasionally)
- III. Strongly disagree/disagree (=never/seldom)

**What are the advantages of using AI?**

- I. AI can speed up the process in diagnosis
- II. AI can help in reducing the number of working length errors
- III. AI can deliver clinically relevant, vast amounts of high-quality data in real time
- IV. AI has no space-time constraint
- V. AI has no emotional exhaustion or physical limitation

**If our judgments and AI judgments differ, which will you follow?**

- I. Doctor's opinion
- II. Artificial intelligence's opinion

- III. Patients' choice
- IV. Expected fields

**Which sector of health care do you think will be the first to commercialize AI?**

- I. Public primary care such as public health centers
- II. Primary care in private clinics
- III. Specialized clinics
- IV. University hospitals

**In which field of endodontics do you think AI will be most useful? Evaluate from 1–5 (1 = least significant, 5 = most significant)**

- I. Making diagnoses
- II. Making the decision for treatment
- III. Working length estimation
- IV. Endodontic research and development
- V. Root fracture
- VI. Periapical pathology
- VII. Smile designing
- VIII. Shade selection
- IX. Bleaching
- X. Patient education
- XI. Prediction of Life threatening crisis on chair
- XII. Electronic medical record analysis
- XIII. Caries detection
- XIV. Dental insurance
- XV. Interdisciplinary treatment protocols
- XVI. CAD/CAM

**Which problems are you concerned about regarding the application of AI in endodontics?**

- I. It cannot be used to provide opinions in unexpected situations owing to inadequate stored information
- II. It is not flexible enough to be applied to every patient
- III. It is difficult to apply to controversial subjects
- IV. Low ability to sympathize and consider the emotional well-being of the patient

- V. It was developed by a specialist with little clinical experience in medical practice

### Who do you think will be responsible for medical problems caused by AI?

- I. Doctor in charge
- II. Company that created the artificial intelligence
- III. Patients who agreed to follow artificial intelligence's input.

## RESULTS

A total of 83 questionnaires were assessed. The majority of the respondents (43.4%) were in the age range of 26 to 35. In which 50 were female and 33 were male. More than half of the participants were in urban (66.7%) or semi urban (16.7%).

### Status of knowledge and use of AI

Most of the respondents rated their knowledge of AI as average (58.3%) above average (25%) or very poor (8.3%) also most of the participants (50%) stated that they never use AI in daily practice. (Figure 1)

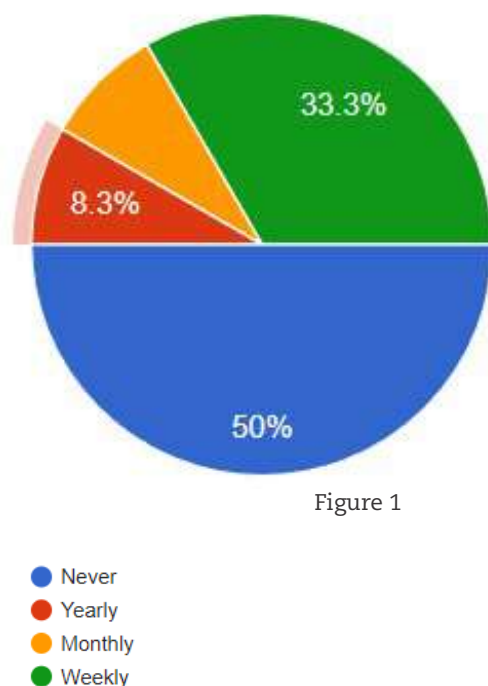


Figure 1

### Predicted impact of AI

The majority of the participants expected AI to impact their profession within 5 years (66.7%), with almost half of them (49%) predicting a positive impact. (Figure 2)

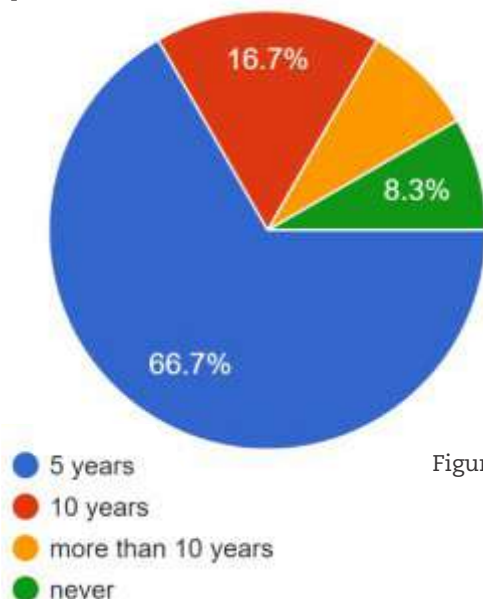


Figure 2

### Perceived advantages of AI

The participants were largely convinced that AI would improve diagnostics and deliver vast high quality data. (Figure 3)

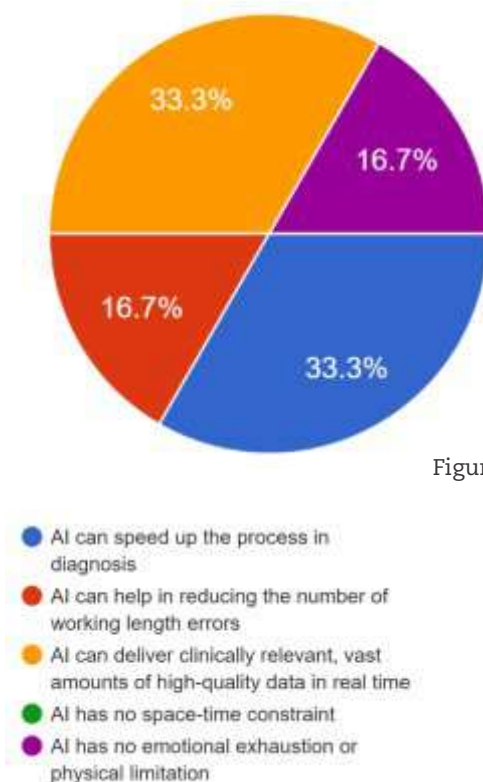


Figure 3

## Perceived Concerns over AI

The responsibility for errors in unexpected situations and not flexible enough to apply to every patient or controversial subjects. Also endodontists are concerned over little knowledge on healthcare by large technology companies. (Figure 4)

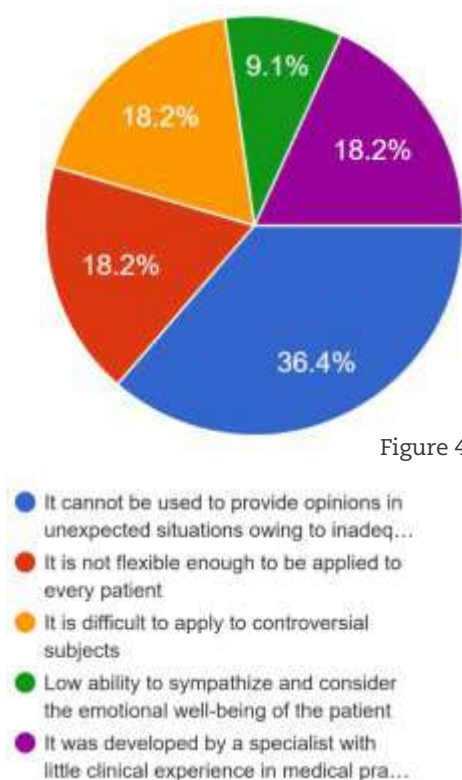


Figure 4

## DISCUSSION

This study aimed to display endodontist's attitude, knowledge, prospects and prognosis regarding the use of AI models in the clinical context. Many studies have investigated the perception of dental or medical students towards AI. However, to the best of our knowledge, no study has been conducted to date on endodontists in the state of Kerala regarding this topic. In the current study, the majority of respondents (58.3%) rated their knowledge of AI as average and reported using AI on a weekly basis ( $p < 0.001$ ). However, a lack of AI knowledge results in a negative attitude towards this technology. One of the reasons for the frequent use of AI in the dental workflow may be the spread of AI-guided treatment planning or intraoral scanning. (Can mention about CBCT and its use in endodontic diagnosis)

Clinicians favored the following major advantages of AI models: In diagnosis of Dental caries, Periapical lesions, Root fractures, Root canal system anatomy, Stem cell viability, Working length determination, Root caries, Analyzing Difficulty level, analyzing Success of retreatment, Locating minor apical foramen, Improved diagnosis, Endodontic research and development, Outcome prediction, Patient education. Smile designing, Shade selection, Bleaching, Evidence based treatment, Prediction of Life threatening crisis on chair, Electronic medical record analysis, Dental insurance, Interdisciplinary treatment protocols, CAD/CAM (If bridge or crowns - to mention about conservative dentistry), 3D reconstruction, Robotics and micro-robotics etc.

Concerns regarding the responsibility for AI-induced errors, The responsibility for AI-induced errors, Privacy and data security matters, unexpected situations, is not flexible enough to be applied to every patient, difficulty in applying to controversial subjects. Low ability to sympathize and consider the emotional well-being. It was developed by a specialist with little clinical experience in medical practice. Despite several serious concerns, clinicians in various surveys agree on the positive impact of AI on their profession.

In a study with medical students from Germany, 83.7% expected AI-derived improvement in medicine. Students from nine Turkish dental schools showed similar results, with 85.7%. This shows that the results of the present study are not only comparable to other surveys of dental healthcare professionals but also applicable to other medical areas.<sup>9</sup>

While the vast majority agreed that AI will revolutionize endodontics (72.2%). Most disagreed that endodontists could be replaced in the foreseeable future (82.9%). One-fourth of respondents were somewhat concerned by the recent developments in AI (25%) AI could be able to extract fine information about tissues invisible to the human eye and process these data quickly and accurately. In other studies, some believe AI will replace doctors in radiology and pathology. A 2017 survey by the Pew Research Center conducted with 4135 participants found that the public is roughly twice as likely to express worry (72%) than



enthusiasm (33%) about a future in which robots and computers are capable of doing many human jobs.<sup>10</sup>

Almost half stated that AI developments make endodontics more exciting to them (54.5%). The vast majority agreed that the use of AI will improve our specialty (85.8%). AI will not replace endodontists, but endodontists that use AI will replace those that do not. Devito et al. achieved an improvement in the diagnosis of proximal caries by 39.4% using an artificial neural network when compared with 25 examiners' diagnoses. Cantu et al. compared dentists against a neural network, which showed a significantly higher accuracy in caries detection.<sup>11</sup>

## CONCLUSION

The purpose of WHO's Global Strategy on Digital Health is to support countries in strengthening their health systems through the application of digital health technologies and achieve the vision of health for all. AI is a Tool, Not a Replacement for Humans. Current study found that endodontists felt the application of AI would be useful and this study emphasizes the need for an additional education in this area to reduce negative attitudes towards AI. Furthermore, this study serves as a basis for future quantitative studies on this topic.

## REFERENCES

1. Taulli T. Artificial Intelligence Basics: A Non-Technical Introduction. 1 ed. Berkeley, CA: Apress (2019). doi: 10.1007/978-1-4842-5028-0\_1 3.
2. Carlos RC, Kahn CE, Halabi S. Data science: big data, machine learning, and artificial intelligence. J Am College Radiol. (2018) 15:497–8. doi: 10.1016/j.jacr.2018.01.029.
3. Ahmed, N.; Abbasi, M.S.; Zuberi, F.; Qamar, W.; Bin Halim, M.S.; Maqsood, A.; Alam, M.K. Artificial Intelligence Techniques: Analysis, Application, and Outcome in Dentistry-A Systematic Review. Biomed Res. Int. 2021, 2021, 9751564.
4. Research Article Retreatment Predictions in Odontology by means of CBR Systems Livia Campo, Volume 2016, Article ID 7485250.
5. Pesapane, F.; Codari, M.; Sardanelli, F. Artificial intelligence in medical imaging: Threat or opportunity? Radiologists again at the forefront of innovation in medicine. Eur. Radiol. Exp. 2018, 2, 35.
6. Gerke, S.; Babic, B.; Evgeniou, T.; Cohen, I.G. The need for a system view to regulate artificial intelligence/machine learning-based software as medical device. NPJ Digit. Med. 2020, 3, 53.
7. Kim C. Chosun.com. Dr Watson and the medical staff...patient URL: [http://news.chosun.com/site/data/html\\_dir/2017/01/12/2017011200289.html](http://news.chosun.com/site/data/html_dir/2017/01/12/2017011200289.html).
8. Scheetz, J.; Rothschild, P.; McGuinness, M.; Hadoux, X.; Soyer, H.P.; Janda, M.; Condon, J.J.J.; Oakden-Rayner, L.; Palmer, L.J.; Keel, S.; et al. A survey of clinicians on the use of artificial intelligence in ophthalmology, dermatology, radiology and radiation oncology. Sci. Rep. 2021, 11, 5193.
9. Eschert, T, M. A Survey on the Use of Artificial Intelligence by Clinicians in Dentistry and Oral and Maxillofacial Surgery. Medicina 2022.
10. Oh S, Kim JH, Choi SW, Lee HJ, Hong J, Kwon SH Physician Confidence in Artificial Intelligence: An Online Mobile Survey J Med Internet Res 2019;21(3):e12422.
11. Gordon Lai, (2023) Artificial Intelligence in Endodontics, Journal of the California Dental Association, 51:1, 2199933, DOI: 10.1080/19424396.2023.2199933.

# ORTHODONTIC TREATMENT IN DIABETIC PATIENTS: CHALLENGES AND CONSIDERATION

## Authors:

Vidya S L<sup>1</sup>

Shikha B<sup>2</sup>

Binnoy Kurian<sup>3</sup>

Post Graduate<sup>1,2</sup>

Department of Orthodontics and  
Dentofacial Orthopaedics  
St Gregorios Dental College

Professor and Head<sup>3</sup>

Department of Orthodontics and  
Dentofacial Orthopaedics  
St Gregorios Dental College

## ABSTRACT

Diabetes mellitus is a metabolic disorder marked by improper regulation of carbohydrates, fats, and proteins due to insulin dysfunction. Dental practitioners must be aware of the oral complications associated with diabetes mellitus (DM) when treating affected patients, as successful orthodontic treatment hinges on proper metabolic control. Orthodontic procedures should be avoided in patients with uncontrolled diabetes (HbA1c > 9%), and treatment can proceed only once blood glucose levels are well-managed. Maintaining good oral hygiene, especially with fixed appliances, is crucial to reduce plaque buildup, tooth decay, and periodontal complications. In conclusion, diabetic patients with good control and proper hygiene can undergo orthodontic treatment successfully, but those with poor metabolic control should defer treatment until their condition stabilizes.

**Keywords:** diabetes mellitus (DM), Type 1 diabetes, Type 2 diabetes, HbA1c, Temporary Anchorage Devices, Orthodontic forces, Sodium lauryl sulfate, Chlorhexidine.

## INTRODUCTION

Diabetes mellitus is a chronic metabolic disorder characterized by elevated blood glucose levels due to insulin deficiency or resistance. Its prevalence has surged globally, making it a significant public health concern. In the field of orthodontics, understanding the implications of diabetes is crucial, as this condition can influence dental health, treatment outcomes, and overall patient management.

Patients with diabetes may experience complications such as delayed wound healing, increased risk of infections, and periodontal issues, all of which can affect orthodontic treatment planning and execution. Additionally, orthodontic forces and appliances can interact with the physiological changes associated with diabetes, necessitating careful consideration by orthodontists.

This article aims to explore the relationship between diabetes and orthodontic care, highlighting the challenges and considerations for practitioners. By understanding these implications, orthodontists can better tailor their approaches to meet the needs of diabetic patients, ensuring effective and safe treatment outcomes.

## UNDERSTANDING DIABETES

Diabetes mellitus is a complex and serious condition characterized by disruptions in carbohydrate, lipid, and protein metabolism. This can occur due to either a significant or complete lack of insulin, often resulting from autoimmune damage to the insulin-producing pancreatic beta cells (known as type 1 or insulin-dependent diabetes mellitus), or from resistance to insulin's effects in target tissues, which is frequently associated with obesity (referred to as type 2 or non-insulin-dependent diabetes mellitus). Type 1 diabetes accounts for no more than 5 percent of all diabetes cases, while type 2 diabetes comprises the majority of cases.

## ORAL HEALTH AND DIABETES

Approximately half of people with diabetes mellitus (DM) are undiagnosed, and a dental

exam may be the first to reveal the condition. Key indicators include dry mucous membranes, oral candidiasis, burning sensations in the mouth, poor wound healing, recurrent infections, and acetone breath. Patients suspected of having DM should be referred for medical evaluation.<sup>1</sup>

Oral manifestations are more common in poorly controlled DM. Well-controlled patients without local factors can have healthy periodontal health. Factors contributing to oral complications include impaired leukocyte function, abnormal collagen metabolism, and prolonged healing times. Decreased saliva flow increases caries risk, while elevated salivary glucose levels can promote bacterial growth, leading to caries and periodontal disease.<sup>1</sup>

Studies show that gingivitis is more severe in children with DM and worsens with higher blood glucose levels. Even well-controlled patients may experience increased gingival inflammation due to impaired neutrophil function. Vascular changes from DM can exacerbate periodontal disease, as confirmed by studies comparing young DM patients with healthy individuals.<sup>1</sup>

While one might expect that normalizing blood glucose would halt periodontal disease progression, this is not always the case. Better metabolic control in type 1 diabetes did not improve periodontal health unless accompanied by good oral hygiene practices.<sup>1</sup>

## IMPLICATIONS FOR ORTHODONTIC TREATMENT

Orthodontist should be aware of the oral complications associated with diabetes mellitus (DM) when treating patients, especially since orthodontic treatment requires good metabolic control. Orthodontic procedures should be avoided in patients with uncontrolled diabetes (HbA1c > 9%). For well-controlled patients, standard dental procedures can proceed without special precautions.<sup>2</sup>

Both fixed and removable appliances can be used, but maintaining good oral hygiene is crucial, as fixed appliances can increase plaque retention, leading to tooth decay and periodontal issues. Regular monitoring of blood glucose levels is important to prevent



complications like candidiasis and unexplained tooth pain due to microangiopathy.<sup>2</sup>

Patients with DM may experience increased gingival inflammation during orthodontic treatment, necessitating careful monitoring of their periodontal health. A full periodontal evaluation should be conducted before starting orthodontics, and any issues should be addressed first. Strict oral hygiene is essential, and adjunctive treatments like chlorhexidine mouth rinses may be beneficial.<sup>2</sup>

There is no upper age limit for orthodontic treatment; however, type 1 DM patients are often more unstable and prone to hypoglycaemia. Morning appointments are preferable, and patients should be advised to maintain their usual diet and medication schedule.<sup>3</sup>

## ORTHODONTIC APPLIANCES AND DIABETES

Orthodontic treatment often involves the use of various appliances, which can impact diabetic patients differently due to their unique oral health needs. Understanding these implications is crucial for effective treatment planning and patient care.<sup>4</sup>

### 1. Types of Orthodontic Appliances

- **Fixed Appliances:** These include braces with brackets and wires. They may pose challenges for diabetic patients, particularly in maintaining oral hygiene, as food can get trapped, increasing the risk of decay and gum disease.
- **Removable Appliances:** These appliances, such as clear aligners, allow for easier cleaning and may be preferable for diabetic patients who struggle with oral hygiene.
- **Temporary Anchorage Devices (TADs):** These may be used to improve treatment efficiency but require careful monitoring in diabetic patients due to healing concerns.

### 2. Impact on Oral Health

Diabetes can exacerbate the challenges associated with orthodontic appliances:

- **Periodontal Health:** Diabetic patients are at a higher risk for periodontal disease, which can

complicate orthodontic treatment and lead to longer treatment times and less favourable outcomes.

- **Healing Process:** Diabetics often experience delayed healing, which can affect the adjustment period to orthodontic appliances. This delay may necessitate adjustments in treatment plans.

## 3. Management Strategies

- **Infection Control:** Rigorous infection control measures should be in place, as diabetic patients are more susceptible to infections, particularly around orthodontic appliances.
- **Regular Monitoring:** Frequent check-ups to monitor oral health and glycaemic control are essential. Orthodontists should collaborate with the patient's healthcare team to ensure comprehensive care.
- **Patient Education:** Educating diabetic patients on maintaining oral hygiene is critical. This includes instructions on how to clean around brackets and wires effectively, as well as the importance of glycaemic control during treatment.<sup>5</sup>

## PATIENT EDUCATION FOR DIABETIC PATIENTS SEEKING ORTHODONTIC TREATMENT

1. **Understanding Diabetes and Oral Health:** Educate patients about how diabetes can affect oral health, including increased risk of gum disease, delayed healing, and oral infections.
2. **Importance of Glycaemic Control:** Emphasize the need for good metabolic control before and during orthodontic treatment. Explain how poor glycaemic control can complicate treatment and increase the risk of periodontal issues.
3. **Pre-Treatment Assessment:** Inform patients about the importance of a thorough dental and medical evaluation before starting orthodontic treatment, including a periodontal examination.
4. **Oral Hygiene Practices:** Provide guidance on maintaining excellent oral hygiene, especially with fixed appliances. Stress the need for regular brushing, flossing, and

possibly using mouth rinses to prevent plaque buildup.

5. **Monitoring and Communication:** Encourage patients to regularly monitor their blood glucose levels and communicate any fluctuations to their orthodontist. Regular updates on their condition can help tailor treatment plans.
6. **Appointment Preparation:** Advise patients on how to prepare for appointments, including dietary considerations and medication management to prevent hypoglycemic events.
7. **Signs of Complications:** Educate patients on recognizing signs of oral complications, such as increased inflammation, pain, or changes in gum health, and encourage them to report these issues promptly.
8. **Support System:** Encourage patients to involve family members or caregivers in their treatment process, ensuring they have support in managing their diabetes and oral health.
9. **Follow-Up Care:** Stress the importance of regular follow-up appointments to monitor both orthodontic progress and overall health, allowing for timely adjustments to treatment if needed.
10. **Holistic Approach:** Reinforce that successful orthodontic treatment is part of a comprehensive approach to managing diabetes, including regular medical check-ups and lifestyle adjustments.<sup>6</sup>

## ORTHODONTIC CONSIDERATIONS

Dental practitioners should be aware of the oral complications associated with diabetes mellitus (DM) when treating affected patients. The foundation of successful orthodontic treatment is effective medical control. Orthodontic procedures should be avoided in patients with uncontrolled diabetes. If a patient's metabolic control is inadequate (> 9%), efforts must be made to improve their blood glucose levels. For patients with good metabolic control, standard dental procedures can be performed without special precautions, provided there are no complications.<sup>7</sup>

There is no specific preference for fixed versus

removable appliances. However, it's crucial to emphasize the importance of good oral hygiene, particularly with fixed appliances, as these can lead to increased plaque retention and a higher risk of tooth decay and periodontal issues. Daily use of fluoride-rich mouth rinses can offer additional preventive benefits. Monitoring blood glucose levels is essential to detect any potential candida infections that may indicate a deterioration in diabetes control.<sup>7</sup>

Occasionally, diabetes-related micro angiopathy may affect the periapical vascular supply, leading to unexplained tooth pain, percussion sensitivity, pulpitis, or even vitality loss in otherwise healthy teeth. During orthodontic treatment, where significant forces are applied to move teeth, practitioners should remain vigilant and regularly check the vitality of the involved teeth. It is advisable to use light forces to avoid overloading the teeth.<sup>7</sup>

In adults, it is particularly important to conduct a full-mouth periodontal examination before starting orthodontic treatment. This should include probing depths, plaque, and gingivitis scores, and an evaluation of the need for any periodontal treatment. The periodontal condition should be improved before beginning orthodontic procedures. During orthodontic treatment, the orthodontist must closely monitor the periodontal condition and control inflammation. As with all orthodontic patients, maintaining strict oral hygiene is crucial. If plaque control is challenging with mechanical aids like toothbrushes and interdental brushes, a chlorhexidine-based disinfectant mouth rinse can be considered as a chemical adjuvant for plaque control. To minimize the neutralizing effect of toothpaste on the chlorhexidine molecule, it is recommended to leave at least a 30-minute interval between toothbrushing and using the chlorhexidine rinse. Chlorhexidine is cationic and forms poorly soluble salts with anions, such as sodium lauryl sulfate, a common detergent in toothpaste, reducing its antimicrobial effectiveness.<sup>7</sup>

Given that there is no upper age limit for orthodontic treatment, practitioners may encounter both type 1 and type 2 diabetes patients. Type 2 patients are generally more stable than type 1 patients, who are often

considered "brittle" and require strict adherence to their medical regimen to maintain blood glucose control. Deviations from an appropriate diet or insulin schedule can cause significant fluctuations in serum glucose levels. Hypoglycaemic reactions may occur more frequently in these patients. Type 1 diabetes is more common in younger patients, who are often candidates for orthodontic treatment. Morning appointments are preferable for these patients. For longer appointments (e.g., 90 minutes), patients should be advised to eat their usual meal and take their medication as normal. At each appointment, before starting any dental procedures, the dental team should confirm that the patient has followed these recommendations to avoid hypoglycaemic reactions during treatment.<sup>7</sup>

## CONCLUSION

Diabetes mellitus (DM), especially when uncontrolled, can be life-threatening due to hypoglycaemic reactions. Dental practitioners must recognize DM symptoms and take a thorough medical history during clinical examinations. If DM is suspected, the patient should be referred for medical evaluation. Well-controlled DM is not a contraindication for orthodontic treatment, but special attention is needed regarding periodontal health. Patients should be informed about the increased risk of gingival inflammation, especially when using fixed appliances, and the importance of maintaining excellent oral hygiene to prevent periodontal issues. Frequent hypoglycaemic episodes may indicate poor diabetic control, and the orthodontist should recommend consulting a physician if signs of worsening control are observed. Orthodontic treatment should be avoided in patients with poorly controlled DM. Those with good metabolic control, good oral hygiene, and no local factors like calculus can be treated orthodontically with outcomes similar to healthy patients.

## REFERENCES

1. ANTHONY T. VERNILLO, D.D.S., Ph.D. Dental considerations for the treatment of patients with diabetes mellitus JADA, Vol. 134, October 2003
2. Little JW, Falace DA, Miller CS, Rhodus NL. Dental management of the medically compromised patient. 6th ed. St. Louis: Mosby; 2002:154, 248-70, 548-632.
3. Expert Committee on the Diagnosis and Classification of Diabetes Mellitus. American Diabetes Association: clinical practice recommendations 2002. Diabetes Care 2002;25(supplement 1): S1-147.
4. Glick, M. (2012). Dental Care for Patients with Diabetes. American Dental Association. Retrieved from ADA.
5. M. M. S. K. Abou Hashish, M. (2015). "Orthodontic Management of Diabetic Patients: A Review." The Egyptian Journal of Otolaryngology, 31(2), 121-126. Doi: 10.1016/j.ejoto.2015.04.001.
6. Kothari, S. (2018). "The Impact of Diabetes on Orthodontic Treatment: A Review." International Journal of Orthodontics, 29(2), 35-42.
7. Luc Bensch, DDS, Marc Braem, DDS, PhD, Kristien Van Acker, MD, PhD, and Guy Willems, DDS, PhD Edegem and Leuven, Belgium Orthodontic treatment considerations in patients with diabetes mellitus Am J Orthod Dentofacial Orthop 2003;123:74-8
8. The Diabetes Control and Complications Trial Research Group. The effect of intensive treatment of diabetes on the development and progression of long-term complications in insulin-dependent diabetes mellitus. N Engl J Med 1993;329:977-86.
9. Ahmed Almadiha, e, Maryam Al-Zayer a, Sukainh Dabela, Ahmed Alkhalafa, Ali Al Mayyada, Wajdi Bardisib, Shouq Alshammaric, Zainab Alsihatid Orthodontic Treatment Consideration in Diabetic Patients J Clin Med Res. 2018;10(2):77-81
10. Geza T, Rose L. Dental correlations for diabetes mellitus. In: Rose LF, Kaye D, editors. Internal medicine for dentistry. 2nd ed. St Louis: C. V. Mosby; 1990. p. 1153.
11. Holtgrave EA, Donath K. Periodontal reactions to orthodontic forces in the diabetic metabolic state. Fortschr Kieferorthop 1989; 50:326-37.
12. Burden D, Mullally B, Sandler J. Orthodontic treatment of patients with medical disorders. Eur J Orthod 2001; 23:363-72

# ORTHODONTIC CORRECTION OF A TRANSPOSED MAXILLARY LATERAL INCISOR AND CANINE

## ABSTRACT

A 10-year-old boy with and ectopically erupting maxillary left canine came for treatment. The transposition of the maxillary canine with lateral incisor was corrected with orthodontic treatment. There was a palatally erupted supernumerary tooth which was extracted at the beginning of treatment. The treatment was successful because the transposition was detected sufficiently early and proper biomechanics could be used to move the canine distally before it was fully erupted.

## Author:

Joseph Varghese

Board-Certified  
American Board of Orthodontics  
Diplomate, Indian Board of Orthodontics  
Orthodontix and More  
Mirador, Muttathil Lane, Kadavanthra  
Cochin 682020, Kerala, India

J Ind Dent Assoc Kochi 2023;6(1):36-42.

## INTRODUCTION

A transposition is usually defined as a rare dental phenomenon in which two adjacent teeth in the arch exchange places. In other words, it is an interchange in position of two permanent adjacent teeth located at the same quadrant in the dental arch. While it may be present both in the maxilla and mandible, transposition between the maxillary canine and first premolar is the most common, followed by maxillary lateral incisor transposed with canine. It causes malalignment of teeth as well as aesthetic and functional problems. Early diagnosis can be made at age 6 to 8 years with a panoramic radiograph, and early orthodontic intervention can correct the problem. When the maxillary canine and lateral incisor are transposed, the lack of resemblance between these two teeth causes unfavourable aesthetics, and thus orthodontic correction may be attempted on a case-to-case basis.

## Diagnosis

JJ, a 10-years 6-months-old boy visited our dental clinic with a chief complaint of an upper tooth erupting in an abnormal position on the right side and also irregular arrangement of teeth. His medical and dental history was not significant. On facial examination, his appearance was symmetrical. He had a good profile and his lips were competent.

On intraoral examination, his oral hygiene was found to be good. He was in the late mixed dentition stage. Caries was detected in #46. There was a supernumerary tooth erupting palatal to #21. The molar relationship was Angle's Class I on both sides. He had moderate crowding of the upper incisors and 4mm crowding of the lower anterior teeth.

OPG revealed no obvious pathology other than the supernumerary tooth as well as transposition of upper lateral incisor and canine on the left side.

Lateral cephalogram revealed a balanced skeletal pattern with mild dental proclination.

## Treatment Objective

The main objectives were extraction of the supernumerary tooth, correction of transposition and crowding.

## Treatment Plan

After the analysis of records, the treatment was planned as follows:

The supernumerary tooth (erupted palatal to #21) and the remaining deciduous teeth (#54, #55, #64 and #75) to be extracted.

A Nance appliance was to be used for anchorage support. The maxillary left canine was to be moved distally with elastomerics, using the first molar for anchorage. The maxillary left lateral incisor would be allowed to move palatally out of the way of the distally-moving canine. After the canine was in a more favorable mesio-distal position, full arch orthodontic treatment with fixed-appliances was to be initiated.

After active treatment, bonded lingual retainers and removable Hawley's Retainers would be used.

## Treatment Progress

After oral prophylaxis, pre-treatment records (intraoral and extraoral photos, study models, OPG and lateral cephalogram) were taken. Orthodontic treatment was started by cementation of Nance appliance and bonding #23 on the disto-labial surface. An elastomeric tubing tie was given from #23 to #26. The elastomeric tubing tie from #23 to #26 was changed regularly every month to retract the tooth.

Three months into treatment, both arches were bonded with pre-adjusted edgewise appliances (0.022" MBT prescription Mini-Sprint Forestadent), except #13 (not fully erupted) and #22 (to allow it to move palatally while #23 was being retracted). NiTi open coil spring was placed from #21 to #24 to hold the space.

#13 was bonded after it had fully erupted. Ten months into treatment, #22 was bonded to bring it into position. Initial levelling and alignment done using 0.016" NiTi arch wires and 0.018" Australian Premium Plus Stainless Steel archwires. Subsequently, 0.019" X 0.025" CuNiTi and 0.019" X 0.025" Stainless steel archwires were used for establishing torque. Throughout treatment, the patient often reported with broken brackets and wires, which were replaced as soon as possible. This caused an increase in the treatment time; the active treatment time was 35 months.



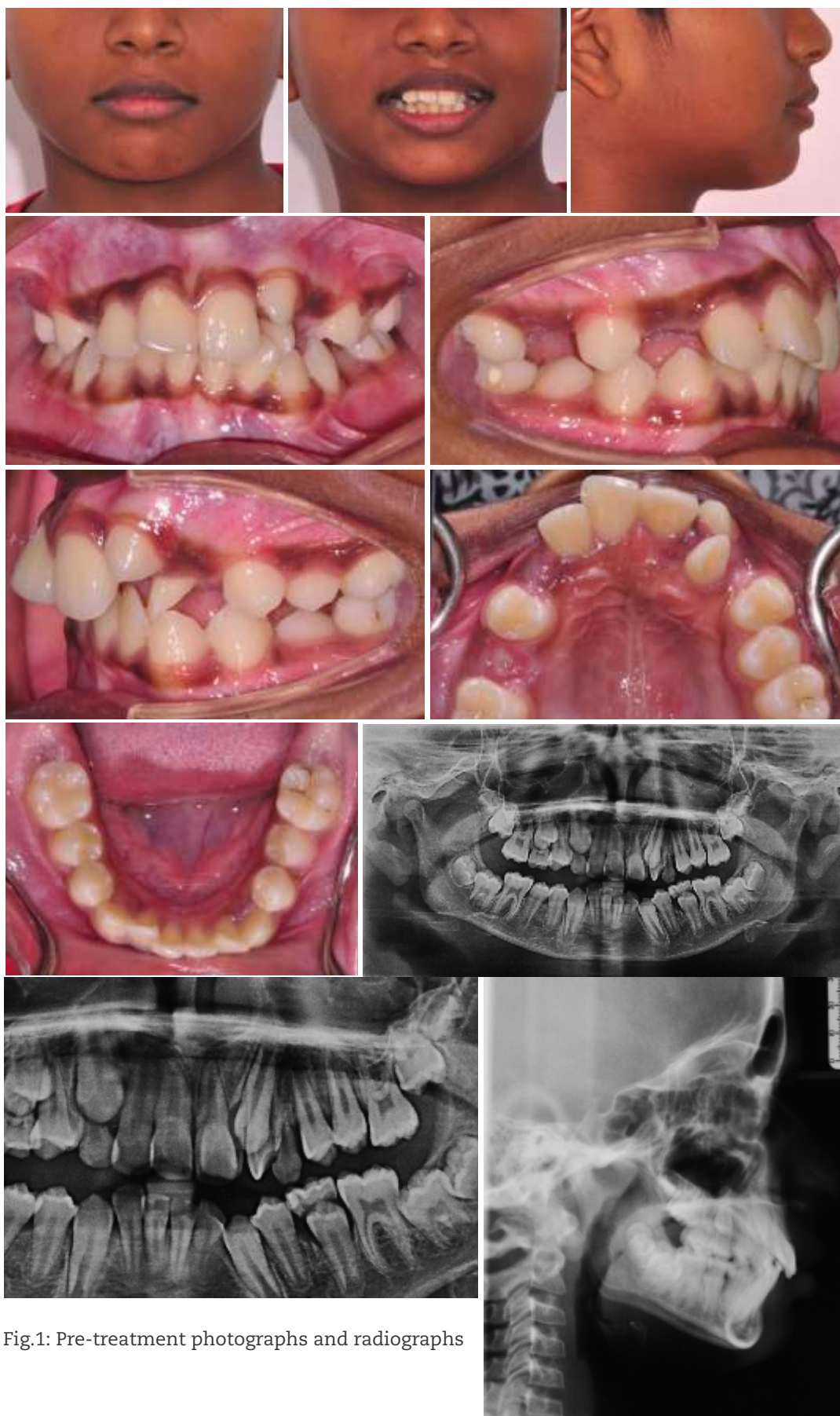

Fig.1: Pre-treatment photographs and radiographs

### Treatment Results

The transposition was successfully corrected and good alignment of the teeth was achieved. The immediate post treatment photographs were taken. However, the patient did not report for post-treatment radiographs or retention checks in spite of several reminders. When he

finally reported three-years post-treatment and photographs and panoramic radiograph were taken. There was relatively good stability of the correction though the patient had lost the bonded retainers and had not worn the Hawley's retainers. The panoramic radiograph also showed horizontally impacted mandibular third molars.

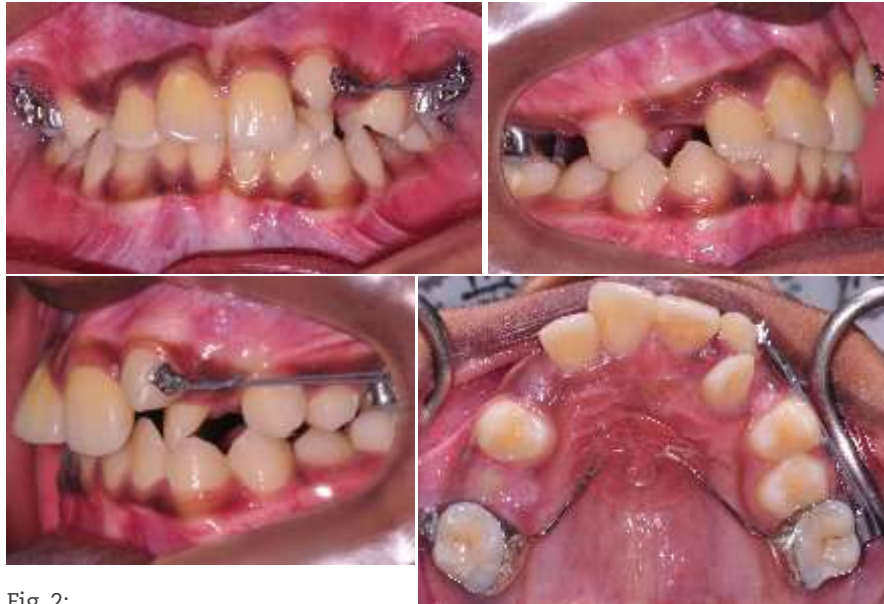

Fig. 2:  
Photographs at the beginning of active treatment

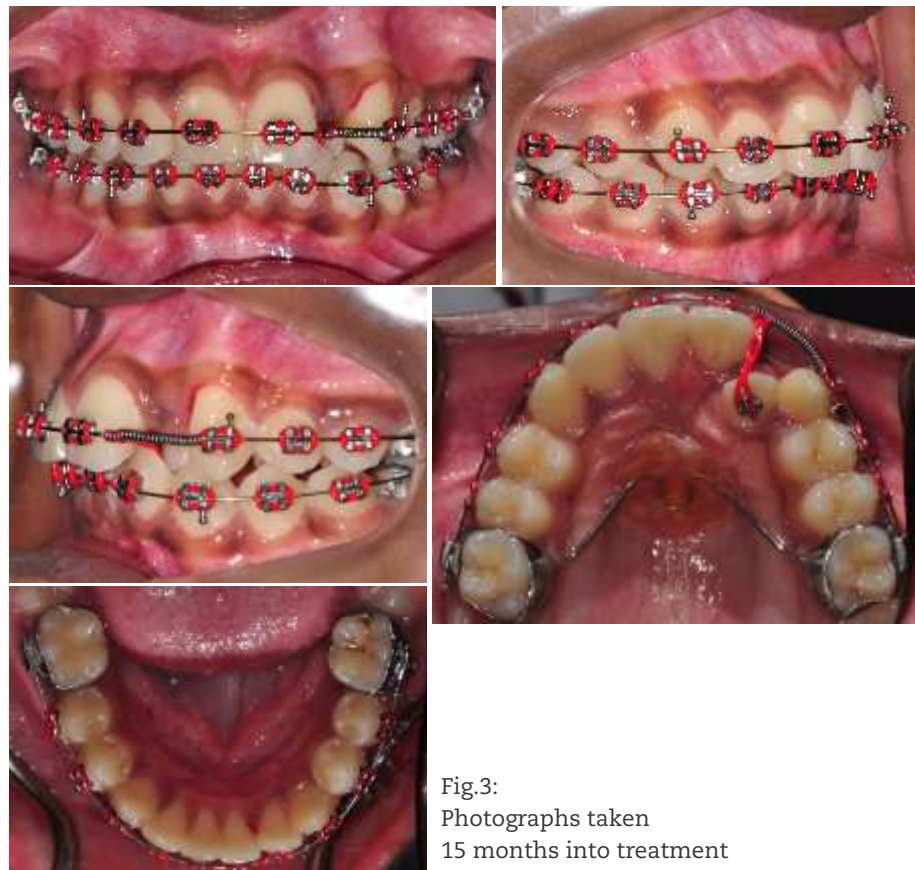


Fig.3:  
Photographs taken  
15 months into treatment



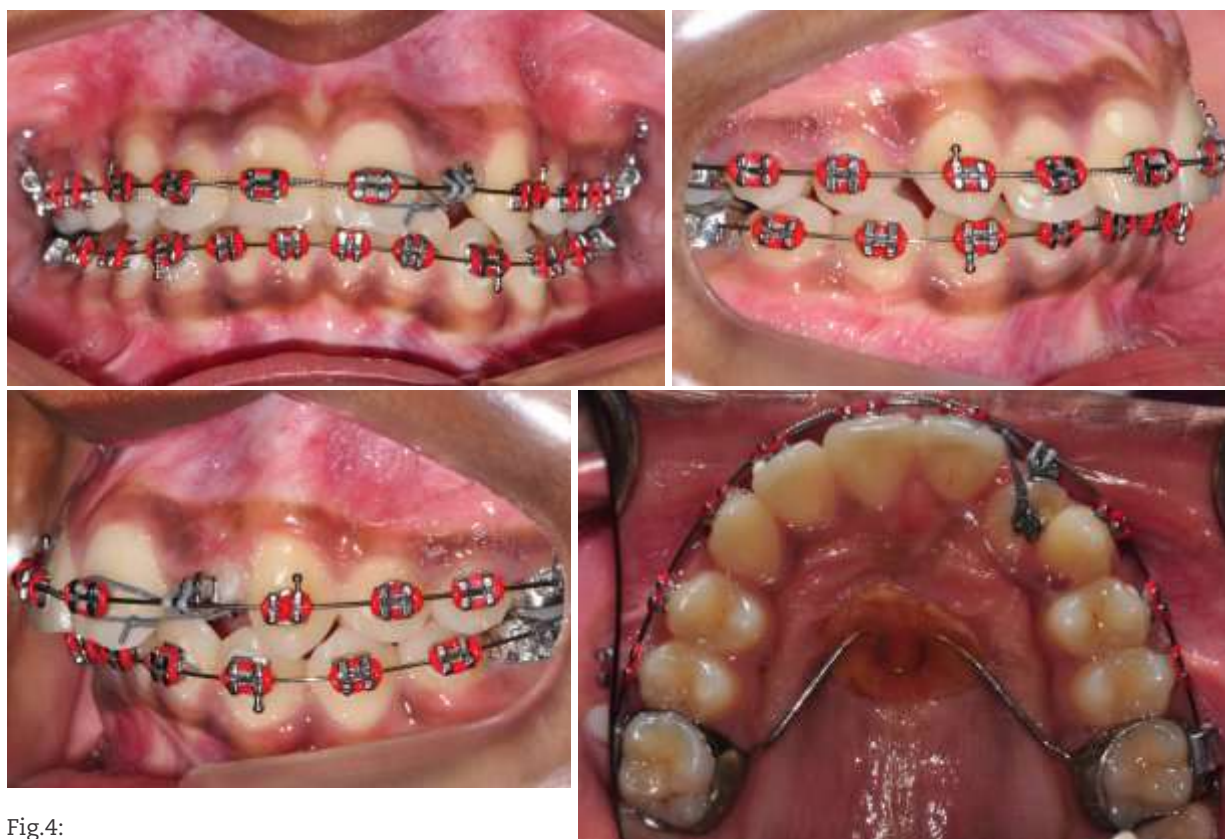


Fig.4:  
Photographs taken 20 months into treatment

Measurement	Pre-treatment
SNA	84
SNB	78
ANB	6
SN-GoGn	31
FMA	26
U 1 to NA (mm)	2
U 1 to SN	108
L 1 to NB (mm)	4
L 1 to GoGn	106
Palatal plane to GoGn	22
L Lip to E plane	3

## Discussion

Various types of tooth transpositions have been described and classified<sup>1,2</sup>. In the maxillary arch, the canine is the tooth most commonly prone to move into abnormal positions in all three dimensions, becoming impacted or transposed. For aesthetic and functional reasons, it is preferable to correct the transposition. While there are several treatment options to correct transpositions, orthodontic correction of the transposed canine is challenging and may not be possible if the root positions are unfavourable and the teeth are fully erupted<sup>3</sup>. The orthodontist must be aware of the potential for iatrogenic harm if these dental anomalies are managed injudiciously. Complications include some amount of external root resorption due to proximity of the root of the tooth being moved as well as gingival recession of the labially placed canine. However, if detected sufficiently early, correction of the transposition can be done especially in instances where the crowns are transposed but the root apices are relatively in their normal positions<sup>4</sup>. During treatment, the lingually placed tooth should not be bonded initially as it is likely to move out of the way on its own provided there is enough bone. The occlusion should be checked for interference with such movement.



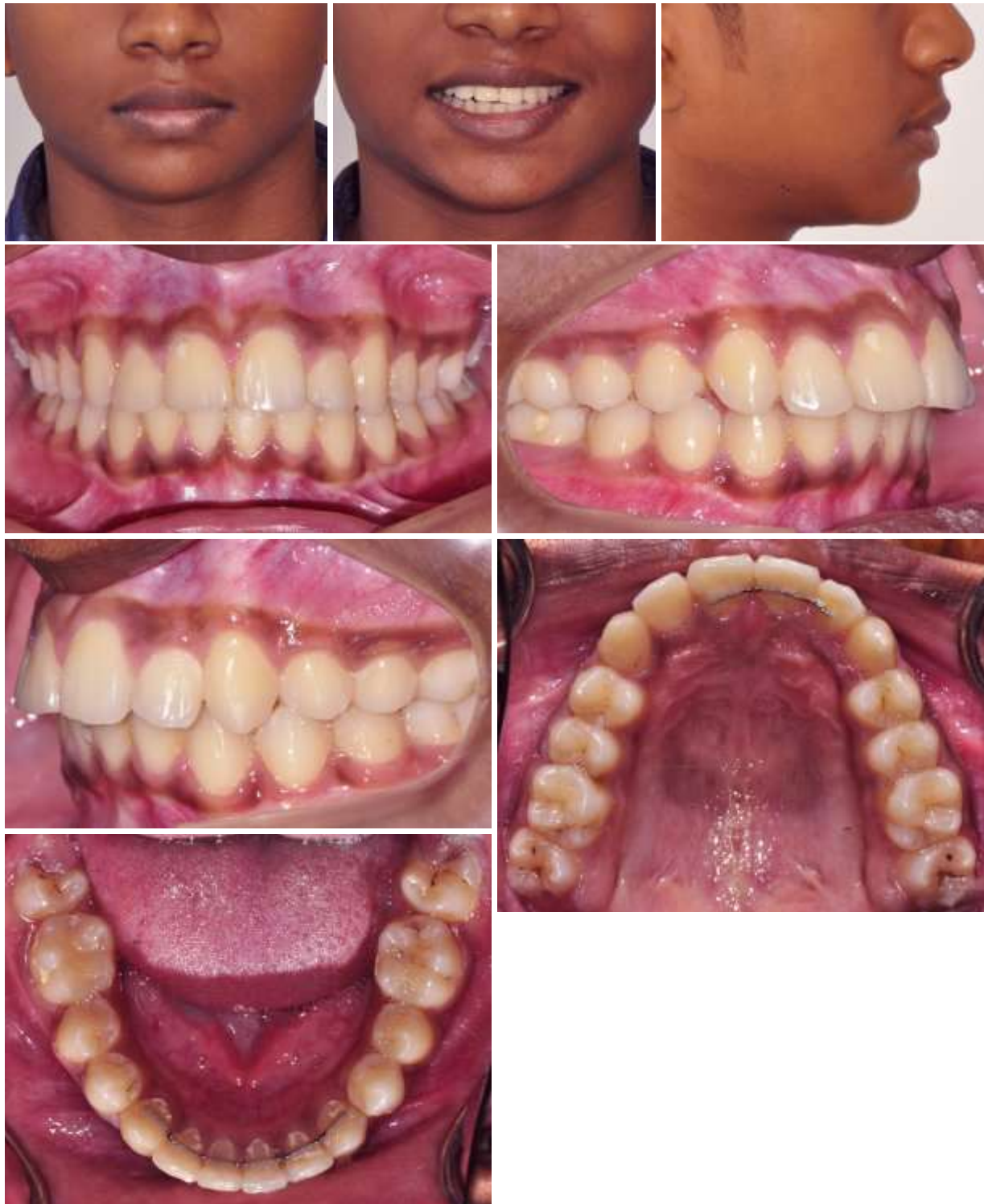


Fig.5:  
Photographs taken  
immediately after treatment

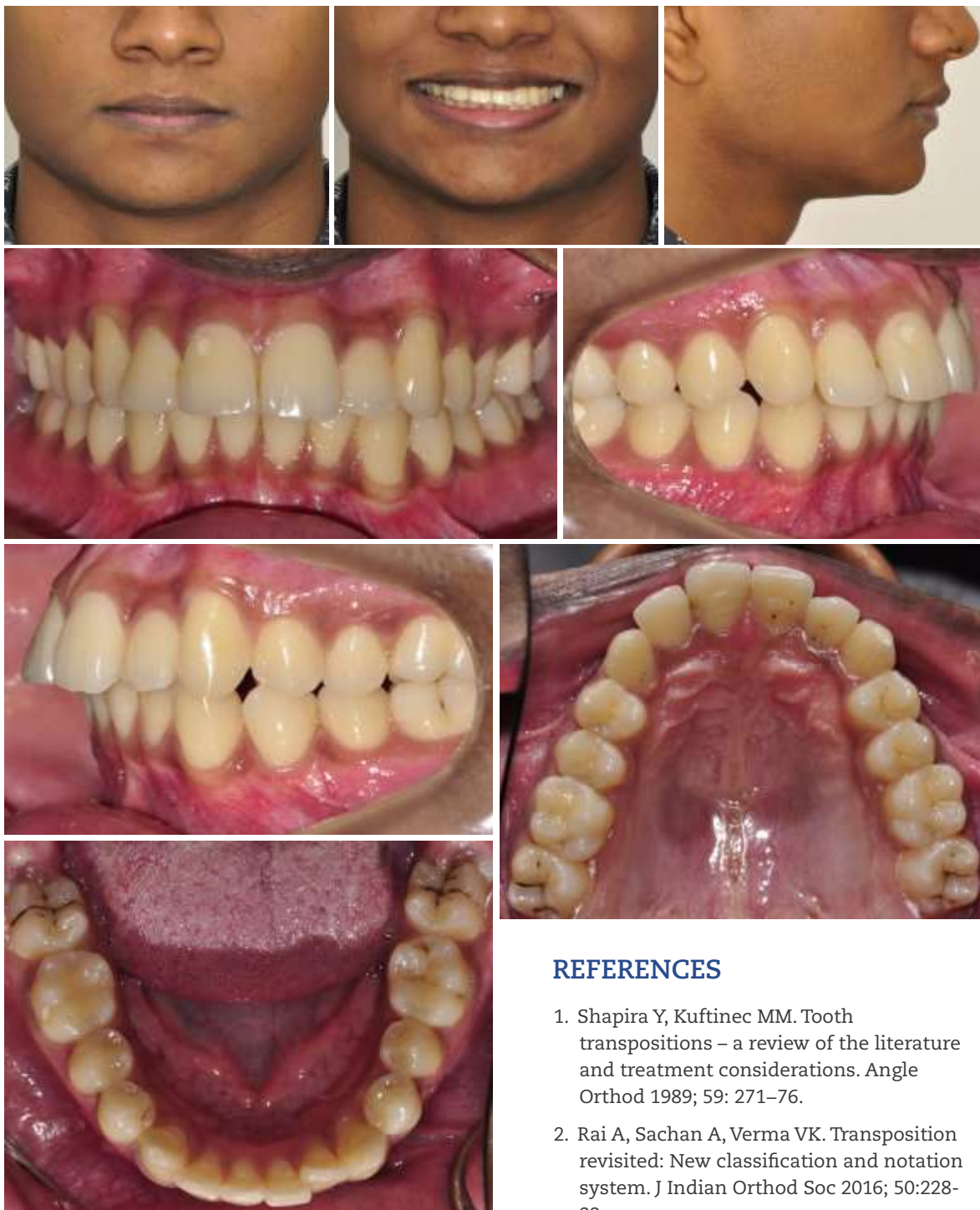

Fig.6:  
Photographs and radiographs  
taken 3 years after treatment

## REFERENCES

1. Shapira Y, Kuftinec MM. Tooth transpositions – a review of the literature and treatment considerations. *Angle Orthod* 1989; 59: 271–76.
2. Rai A, Sachan A, Verma VK. Transposition revisited: New classification and notation system. *J Indian Orthod Soc* 2016; 50:228–33.
3. Sabri R, Zaher A, Kassem H. Tooth transposition: a review and clinical considerations for treatment. *World J Orthod* 2008; 9:303–318.
4. Shapira Y, Kuftinec MM. Maxillary canine-lateral incisor transposition: orthodontic management. *Am J Orthod Dentofacial Orthop* 1989; 95:439–44.

# CUSHING'S SYNDROME: A SUMMATION

## Authors:

Bastin Bright Cherian<sup>1</sup>

Sharlene Sara Babu<sup>2</sup>

Sunil S<sup>3</sup>

Intern<sup>1</sup>

Additional Professor<sup>2</sup>

Professor and Head<sup>3</sup>

Department of

Oral & Maxillofacial Pathology

Pushpagiri College of Dental Sciences

## ABSTRACT

Cushing's syndrome is a disorder characterized by prolonged exposure to elevated levels of cortisol . It can result from various etiologies, including endogenous sources like pituitary adenomas or exogenous sources such as glucocorticoid medications . This syndrome presents with diverse symptoms, including central obesity, hypertension, and glucose intolerance, leading to significant morbidity if untreated . This article provides an overview of Cushing's syndrome, focusing on its pathophysiology, clinical presentation, diagnostic challenges, and treatment options. Understanding these aspects is crucial for timely diagnosis and effective management to improve patient outcomes .

J Ind Dent Assoc Kochi 2024;6(2):31-5.



## INTRODUCTION

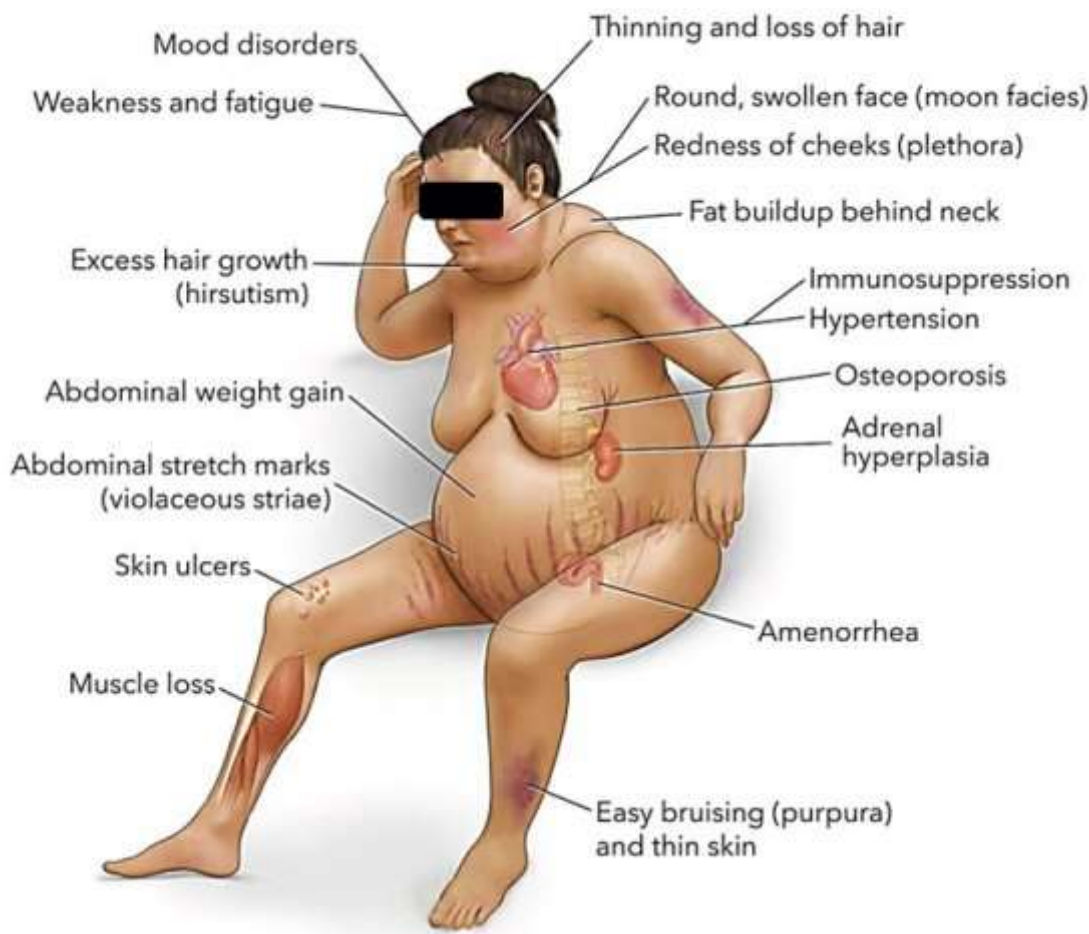
Cushing's syndrome is a complex endocrine disorder resulting from chronic exposure to excessive cortisol levels<sup>1</sup>. The condition is relatively rare but has significant health implications due to its multisystem involvement<sup>2</sup>. The syndrome can be classified into two broad categories: endogenous Cushing's syndrome, caused by internal factors like pituitary adenomas (Cushing's disease) or adrenal tumors, and exogenous Cushing's syndrome, primarily due to prolonged use of glucocorticoid medications<sup>3</sup>. Prompt detection and correct diagnosis are crucial for effective management and improving patient prognosis<sup>4</sup>.

## Discussion

Cushing's syndrome arises from long-term exposure to elevated levels of cortisol, a glucocorticoid hormone produced by the

adrenal glands<sup>1</sup>. Cortisol plays a vital role in regulating metabolism, immune response, and stress. In endogenous Cushing's syndrome, excessive cortisol production is often due to pituitary adenomas secreting adrenocorticotrophic hormone (ACTH), known as Cushing's disease, or from adrenal adenomas and carcinomas producing cortisol autonomously<sup>2</sup>. Non-pituitary sources of ACTH production, such as small cell lung carcinoma, can also cause Cushing's syndrome<sup>3</sup>.

Individuals with hypercortisolism exhibit a range of symptoms, including central obesity, facial rounding (moon face), and dorsocervical fat pad (buffalo hump)<sup>1</sup>. Metabolic complications include glucose intolerance, hypertension, and dyslipidemia<sup>2</sup>. Osteoporosis and increased fracture risk are common due to the catabolic effects of cortisol on bone tissue<sup>5</sup>. Psychological disturbances, such as depression, anxiety, and cognitive impairments, significantly impact the well-being of the patient<sup>6</sup>.



The diagnostic approach for Cushing's syndrome involves confirming hypercortisolism and identifying its source<sup>1</sup>. Initial screening tests include 24-hour urinary free cortisol, Night time cortisol levels, and dexamethasone suppression test with low-dose<sup>2</sup>. Once hypercortisolism is confirmed, further testing, such as dexamethasone suppression test with high-dose, plasma ACTH levels, and imaging studies (MRI for pituitary tumors, CT scan for adrenal tumors), helps determine the underlying cause<sup>3</sup>.

Treatment strategies for Cushing's syndrome depend on the underlying cause. Surgical resection of pituitary adenomas, adrenal tumors, or ectopic ACTH-secreting tumors is the primary treatment for endogenous Cushing's syndrome<sup>1</sup>. In cases where surgery is not feasible or unsuccessful, medical therapies such as ketoconazole, metyrapone, and osilodrostat are used to control cortisol levels<sup>7</sup>. Radiation therapy may be considered for persistent or recurrent pituitary tumors<sup>8</sup>. Management of exogenous Cushing's syndrome involves tapering and discontinuing glucocorticoid medications when possible<sup>1</sup>.

Despite successful treatment, patients with Cushing's syndrome often experience long-term complications and Lowered standard of living<sup>6</sup>. Persistent metabolic abnormalities, increased cardiovascular risk, and psychological issues are common post-treatment concerns<sup>9</sup>. Regular follow-up and supportive care are essential to manage these chronic effects and improve patient outcomes<sup>10</sup>.

## Conclusion

Cushing's syndrome is a multifaceted endocrine disorder with significant health implications due to prolonged cortisol exposure. Early diagnosis and tailored treatment strategies are crucial for managing the syndrome effectively and reducing morbidity. Despite treatment, long-term follow-up is necessary to address persistent complications and enhance the standard of living for affected patients. Ongoing research and advancements in diagnostic and therapeutic approaches hold promise for better management and outcomes in Cushing's syndrome.

## REFERENCES

1. Lodish MB, Keil MF, Stratakis CA. Cushing's Syndrome in Pediatrics: An Update. *Endocrinol Metab Clin North Am*. 2018 Jun;47(2):451-462. doi: 10.1016/j.ecl.2018.02.008. PMID: 29754644; PMCID: PMC5962291.
2. Paragliola RM, Corsello A, Papi G, Pontecorvi A, Corsello SM. Cushing's Syndrome Effects on the Thyroid. *Int J Mol Sci*. 2021 Mar 19;22(6):3131. doi: 10.3390/ijms22063131. PMID: 33808529; PMCID: PMC8003177.
3. Hamblin R, Coulden A, Fountas A, Karavitaki N. The diagnosis and management of Cushing's syndrome in pregnancy. *J Neuroendocrinol*. 2022 Aug;34(8) doi: 10.1111/jne.13118. Epub 2022 May 1. PMID: 35491087; PMCID: PMC9541401.
4. Kim YJ, Lee KA. Cushing's syndrome: a rare cause of multiple vertebral fractures shortly after a complicated pregnancy. *Korean J Intern Med*. 2022 Jan; 37(1):247-248. Doi: 10.3904/kjim.2021.243. E pub 2021 Jul 28. PMID: 34320308; PMCID: PMC8747926.
5. Webb SM, Valassi E. Quality of life impairment after a diagnosis of Cushing's syndrome. *Pituitary*. 2022 Oct;25(5):768-771. doi: 10.1007/s11102-022-01245-9. Epub 2022 Jun 29. PMID: 35767164; PMCID: PMC9587961.
6. Juszczak A, Grossman A. The investigation of Cushing syndrome: essentials in optimizing appropriate diagnosis and management. *Ann Saudi Med*. 2012 Sep-Oct;32(5):455-61. doi: 10.5144/0256-4947.2012.455. PMID: 22871612; PMCID: PMC6080996.
7. Działach L, Sobolewska J, Respondek W, Wojciechowska Luzniak A, Witek P. Cushing's syndrome: a combined treatment with etomidate and osilodrostat in severe life-threatening hypercortisolemia. *Hormones (Athens)*. 2022 Dec;21(4):735-742. doi: 10.1007/s42000-022-00397-4. Epub 2022 Sep 21. PMID: 36129663; PMCID:

PMC9712315.

8. Fushimi Y, Tatsumi F, Sanada J, Shimoda M, Kamei S, Nakanishi S, Kaku K, Mune T, Kaneto H. Concurrence of overt Cushing's syndrome and primary aldosteronism accompanied by aldosterone-producing cell cluster in adjacent adrenal cortex: case report. *BMC Endocr Disord*. 2021 Aug 12;21(1):163. doi: 10.1186/s12902-021-00818-2. PMID: 34384396; PMCID: PMC8359021.
9. Birdwell L, Lodish M, Tirosh A, Chittiboina P, Keil M, Lyssikatos C, Belyavskaya E, Feelders RA, Stratakis CA. Coagulation Profile Dynamics in Pediatric Patients with Cushing Syndrome: A Prospective, Observational Comparative Study. *J Pediatr*. 2016 Oct;177:227-231. doi: 10.1016/j.jpeds.2016.06.087. Epub 2016 Aug 2. PMID: 27496264; PMCID: PMC5298225.

Marchand L, Segrestin B, Lapoirie M, Favrel V, Dementhon J, Jouanneau E, Raverot G. Dilated Cardiomyopathy Revealing Cushing Disease: A Case Report and Literature Review. *Medicine (Baltimore)*. 2015 Nov;94(46):e2011. doi: 10.1097/MD.0000000000002011. PMID: 26579807; PMCID: PMC4652816





# JIDAK

JOURNAL OF INDIAN DENTAL ASSOCIATION - KOCHI